

Achalasia: Update on the Disease and Its Treatment

DAWN L. FRANCIS and DAVID A. KATZKA

Division of Gastroenterology and Hepatology, Mayo Clinic, Rochester, Minnesota

Podcast interview: www.gastro.org/gastropodcast.

Epidemiology

Most studies that evaluate the epidemiology of achalasia are retrospective. Studies on the incidence and prevalence of achalasia come mostly from the United Kingdom, but there have been also studies of diverse populations such as Northern Europe, Israel, New Zealand, the United States, and Zimbabwe.¹⁻⁵ These studies indicate that the incidence is approximately 1 in 100,000 individuals annually and the prevalence is 10 in 100,000. There is no gender predominance and the disease can occur at any age, although diagnosis before the second decade is rare⁶ and the incidence increases with age, with the highest incidence in the seventh decade⁷ and a second smaller peak of incidence at 20–40 years of age.⁸

Pathophysiology

Normally, a food bolus introduced to the esophagus is moved to the stomach via a coordinated peristaltic wave and relaxation of the lower esophageal sphincter (LES) that depends on both excitatory and inhibitory input from the enteric neural plexus and extrinsic innervation of the vagus nerve. Achalasia results from a disruption of these normal functions.

Using histologic analysis of myotomy and esophagectomy specimens from patients with primary achalasia, it has been demonstrated that the dysfunction results from degeneration of ganglion cells in the myenteric plexus of the esophageal body and the LES.⁹ Immunohistochemical techniques reveal that the loss of ganglion cells is often accompanied by inflammatory infiltrates with lymphocytes that has led to the notion that the etiology is either autoimmune, viral immune, or neurodegenerative.¹⁰

The triggering event that leads to ganglion cell degeneration in achalasia is unclear. Some investigators have suggested a genetic predisposition as shown by associations with class II human leukocyte antigen DQw1¹¹ or specific human leukocyte antigen (HLA) classes, myenteric antiplexus antibodies with specific HLA genotypes,¹² and gender-specific polymorphism associated with women with achalasia.¹³ An abnormal vasoactive intesti-

nal peptide receptor 1 gene was found in older patients with achalasia.¹⁴

Molecular mimicry has been invoked through an initial virally mediated injury, as is the case with measles, herpes virus, varicella zoster, poliovirus, and human papilloma virus. The most compelling evidence that achalasia is an immune-mediated response to a virus in a genetically susceptible population comes from Facco et al, who produced clonal cytotoxic T cells removed from the gastroesophageal junction of patients with achalasia in response to herpes simplex virus-1. Thus, herpes simplex virus-1 infection could cause a myenteric plexitis and self-mediated neuronal destruction in genetically susceptible patients.¹⁵ However, polymerase chain reaction assays of achalasia specimens have not shown viral products in esophageal tissue and no study has clearly established a causal link between achalasia and viral infection.

There has been work regarding achalasia as an autoimmune phenomenon. A recent case-control study evaluated the serum of 70 patients with primary achalasia and found a higher prevalence of neural autoantibodies in patient than controls.¹⁶ One recent study suggests that a loss of esophageal interstitial cells of Cajal may contribute to the disease.¹⁷ Antineuronal antibodies (anti-Hu) may be associated with achalasia but only in the presence of malignancy. Muscarinic antibodies have been found in patients with primary achalasia but are more commonly found in Chagas disease.¹⁸ Unfortunately, no single antibody type can be demonstrated reliably in achalasia patients.

The result of esophageal plexopathy is disruption of normal peristalsis and relatively greater loss of nitric oxide in the LES. Why nitric oxide is selectively targeted is unclear. Regardless, with loss of this major inhibitory neurotransmitter, the LES develops hypertonicity and incomplete relaxation of tone with swallowing.

In some cases, achalasia is due to a known cause. For example, there is an autosomal recessive syndrome linked to a mutation on chromosome 12q13 known as “Allgrove’s syndrome” or the “4A syndrome” that involves achalasia, alacrima, autonomic disturbance, and cortico-

tropin (ACTH) insensitivity. Achalasia can be caused by infiltration of the esophagus and LES in amyloidosis or owing to extrinsic compression of the gastroesophageal junction, as may occur with tight fundoplication during antireflux procedures¹⁹ or laparoscopic adjustable gastric banding.²⁰ Achalasia is known to occur after infection by *Trypanosoma cruzi*, also known as Chagas disease. Patients with this infection often have other features of diffuse enteric myenteric destruction, including megacolon, heart disease, and neurologic disorders, although the phenotypic manifestations are linked to geographic variation in endemic countries.

The most common cause of secondary achalasia is malignancy through one of several mechanisms. Tumors that infiltrate the gastroesophageal junction may cause an achalasia-like picture from extrinsic pressure or direct tumor invasion of the myenteric plexus. This is most commonly described with adenocarcinoma of the gastroesophageal junction or proximal stomach, but may occur with pancreatic, breast, lung, or hepatocellular cancers. Cancer, most commonly small cell lung cancer, may produce achalasia through a paraneoplastic effect by secretion of an antineuronal antibody.

Clinical Presentation

Most patients with achalasia present with esophageal dysphagia (present in up to 90% of patients), often for both solids and liquids, a distinction from anatomic disorders of the esophagus. Other common symptoms include chest pain, heartburn, regurgitation, and weight loss, all of which occur in up to 60% of patients. Patients with achalasia may also present with more subtle symptoms owing to accommodation. These symptoms might

include slow eating, stereotactic movements with eating, and avoidance of social functions that involve meals. With these self-taught accommodating techniques, the onset of symptoms in patients can be slow in progression and many patients experience symptoms for years before coming to medical attention.²¹ Patients with achalasia may also present with heartburn owing to bacterial fermentation, and thus acidification, of food products within the esophagus. As a result, reflux symptoms unresponsive to reflux therapy may suggest achalasia.

Diagnosis

Patients who have a history that suggests achalasia commonly require at least 2, and sometimes 3, modalities for diagnosis.²² Barium esophagram is often the first study performed for patients with dysphagia. In patients with achalasia with severe symptoms, there is typically a dilated esophagus, absence of peristalsis, and narrowing of the distal esophagus in a typical “bird’s beak” appearance but the radiographic appearance of achalasia can be variable (Figure 1). The number and severity of findings on esophagram often do not correlate with the degree of symptoms a patient with achalasia has, but at least 1 of these features is present in virtually all cases of achalasia.²³ This study alone may be diagnostic, particularly in advanced cases.

Endoscopic evaluation of the esophagus and stomach is recommended in every patient with achalasia to ensure that there is not a malignancy causing the disease or esophageal squamous cell carcinoma complicating achalasia. At endoscopy, a dilated esophagus with a tight LES that “pops” open with gentle pressure is often observed, as is retained food and saliva. However, a normal esopha-

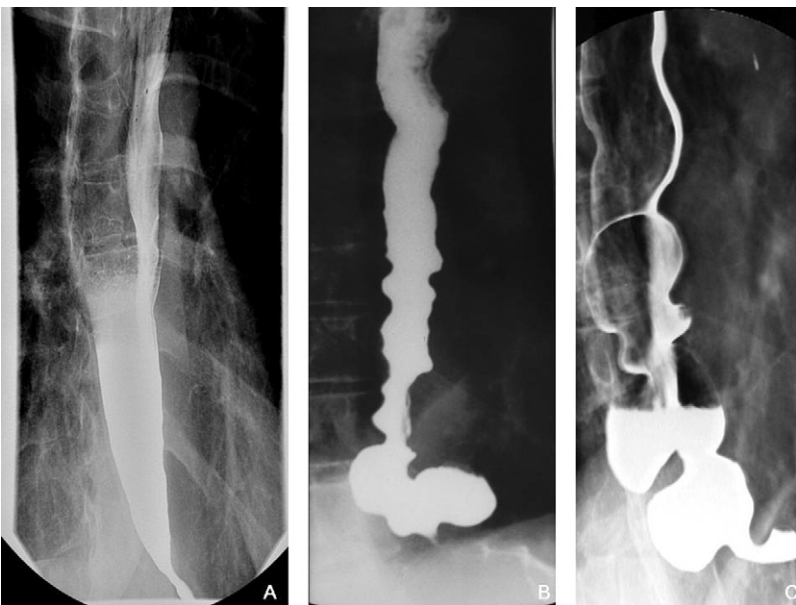

Figure 1. Barium esophagrams on achalasia patients demonstrating a dilated esophagus and tapering of the distal esophagus with the classic “bird’s beak” (A), diffuse narrowing of the esophagus with a spastic appearance often seen in “vigorous” achalasia and a large epiphrenic diverticulum (B), and a dilated and tortuous esophagus with early “sigmoidization” of the esophagus (because of its visual similarity to the sigmoid colon on barium enema) observed in long standing achalasia accompanied by multiple pulsion diverticuli (C).

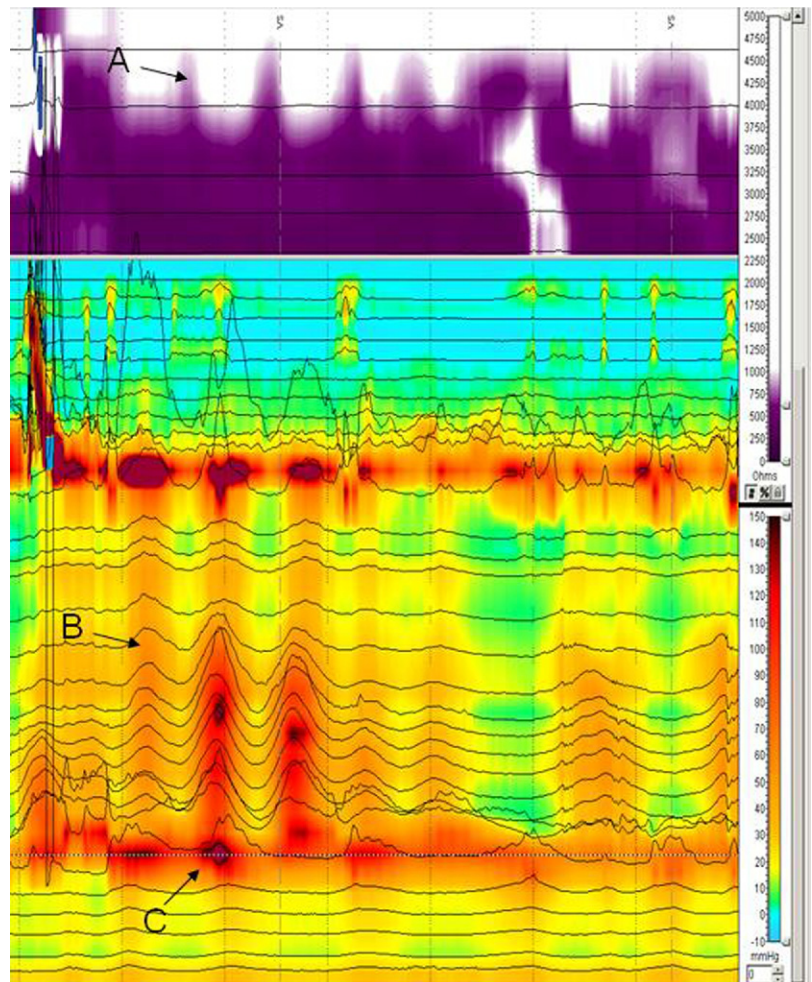


Figure 2. High-resolution esophageal manometry with impedance on an achalasia patient revealing aperistalsis and incomplete bolus transit demonstrated by impedance (A), isobaric simultaneous contractions (B), and a hypertensive and poorly relaxing LES (C).

gogastroduodenoscopy should not dissuade a clinician from making the diagnosis because up to 40% of patients with achalasia will have a normal endoscopy.²⁴

Esophageal manometry is considered the gold standard diagnostic modality for achalasia. Manometrically, classic achalasia is defined by absence of peristalsis in the esophageal body, a hypertensive LES (resting pressure >45 mm Hg) and a poorly relaxing LES, with a residual pressure >8 mm Hg. However, it is well understood that as many as 50% of patients that are given the clinical diagnosis of achalasia do not have a hypertensive LES,²⁵ although the diagnosis does require aperistalsis and a poorly relaxing LES.^{26,27}

High-resolution manometry and multichannel intraluminal impedance with manometry have been applied to achalasia (Figure 2). Using high-resolution manometry, achalasia has been divided into 3 subtypes based on the function of the esophageal body with the notion that different subtypes may respond to treatment in a variable fashion. Type I (classic achalasia has no distal esophageal pressurization >30 mm Hg); type II (achalasia with esophageal compression) has ≥ 2 test swallows associated

with an esophageal pressurization >30 mm Hg, and type III (spastic achalasia) patients have ≥ 2 spastic contractions with or without a period of compartmentalized pressurization. These investigators used logistic regression and found that type II achalasia patients were more likely to have good symptom response and less likely to require multiple treatments than the other 2 groups.

With reevaluation of the manometric criteria for achalasia, some diseases may commonly be called achalasia variants.²⁸ For example, diffuse esophageal spasm, which may be defined manometrically by a hypertensive LES and some simultaneous contractions, may progress to achalasia. Indeed, some patients with insufficient manometric criteria undergo classic barium esophagograms for achalasia. As a result, diagnosis of achalasia often becomes a compilation of compatible clinical and objective criteria rather than reliance on a single test.

Treatment

Therapy of achalasia focuses on relaxation or mechanical disruption of the LES. Achalasia is rare so there

are few randomized, controlled clinical trials that can define the optimal strategy. The safety, effectiveness, and durability of current treatment options vary widely.

Medications

A number of medications have been used in achalasia including nitrates,²⁹ calcium channel blockers,³⁰ and nitric oxide donors (sildenafil)³¹ in an attempt to either facilitate LES relaxation and/or augment esophageal peristalsis. Unfortunately, adverse side effects and a general lack of efficacy have precluded common use of these medications for achalasia.

Endoscopic Treatments

Endoscopic botulinum toxin injection (EBTI) into the LES inhibits the release of acetylcholine from nerve endings thereby relaxing muscles. The injection of botulinum toxin into the LES is an appealing strategy; it is safe, easy to perform, inexpensive, and effective.^{32,33} A variety of studies have looked at the efficacy and durability of botulinum toxin injection and have found excellent short-term symptomatic improvement, although repeat injections are commonly required.³⁴ The long-term safety and efficacy are less certain.^{34,35} There is some evidence that injection of botulinum toxin into the LES is associated with increased difficulty of performing esophagomyotomy at a later date.³⁶ For this reason, many clinicians reserve the use of botulinum toxin for patients who are of extreme advanced age or who have severe comorbidities that preclude treatment with pneumatic balloon dilation or esophagomyotomy because of their associated risks.

Dilation of the LES in patients with achalasia should be aimed at fracturing the muscularis propria. Bougienage or standard balloon dilation are typically ineffective in achalasia, but pneumatic balloon dilation with a rigid balloon across the LES has been shown to be effective and inexpensive.^{37,38} It is typically performed using a guidewire and fluoroscopy to position the balloon across the LES. Recently, investigators have performed pneumatic dilation using direct visualization rather than fluoroscopy to limit radiation exposure and to improve clinical remission and complications. Although this endoscopically guided dilation is as effective as the traditional fluoroscopically guided technique, it did not have fewer complications or better response rates.³⁹ The drawbacks of pneumatic dilation are that there is an esophageal perforation rate between 2% and 6% (depending on the series and technique)⁴⁰ and lack of durability compared with operative treatment in most studies.⁴¹ Although patients who sustain perforation may have effective completion myotomy emergently, experience with emergent laparoscopic repair is preliminary⁴² and often necessitates open laparotomy.

Some investigators debate the role of injection of botulinum toxin injection versus pneumatic dilation. A recent Cochrane Review that included 6 randomized, controlled trials with 178 patients evaluated symptom recurrence after esophageal dilation versus endoscopic botulinum toxin injection at 1, 6, and 12 months after treatment. Thirty percent of patients undergoing dilation experienced symptom recurrence and treatment failure at 12 months versus 74% of patients who received EBTI.⁴³

Furthermore, a systematic review and meta-analysis of 105 articles that reported on 7855 patients with achalasia who underwent endoscopic treatment with esophageal dilation or EBTI showed that symptom relief was better for dilation than for EBTI and the necessity of further procedures was reduced.⁴⁴

The role of pneumatic dilation in comparison to surgery is less clear. There has been a single randomized prospective trial examining esophagomyotomy versus pneumatic dilation.⁴⁵ This study showed equivalent results regarding effectiveness at relieving symptoms initially, but at follow-up showed that patients who had esophagomyotomy had fewer recurrent symptoms than those who had pneumatic dilation. Some studies suggest that pneumatic dilation may achieve long-term relief of symptoms,⁴⁶ particularly in patients >50 or 60 years old or when compared retrospectively with myotomy and, consequently, should be offered as a treatment to patients with achalasia.

Surgery

Esophagomyotomy or Heller myotomy divides LES from serosa to mucosa, thereby completely disrupting the muscular layers. A longitudinal incision is initiated on the gastric side approximately 2 cm distal to the gastroesophageal junction and extended proximally 7 cm above the junction. Over the past 20 years, this procedure has been performed safely and successfully laparoscopically^{47,48} and more recently with the assistance of computer guidance and a robotic arm.⁴⁹ Long-term studies show that surgical myotomy may result in symptomatic relief in 80% to 85% of patients when followed for 10 years.^{50,51} There is mounting evidence, however, that the learning curve, particularly when performed laparoscopically, is steep, requiring >200 procedures. This has been shown to lead to fewer complications and a shorter duration of hospitalization.⁵²

Heller myotomy is not effective in every case, and some patients require reoperation or esophagectomy. The best predictor of patients who will require additional intervention after Heller myotomy is esophageal dilation of >6 cm in diameter before surgery, a condition known as megaesophagus. Patients who have severe dilation of the esophagus have a higher rate of reoperation with esophagectomy, although the majority of these patients

(>90%) do not require esophagectomy.^{53,54} Most experts advocate that patients with megaesophagus be treated with Heller myotomy initially.

Nearly 50% of patients who have a modified Heller myotomy progress to develop gastroesophageal reflux disease,⁵⁵ with some developing erosive esophagitis, stricture, and Barrett's esophagus. This has led to the common practice of coupling the modified Heller myotomy with a fundoplication in most centers. Initially, a "floppy" Nissen fundoplication was used, but more recently there has been widespread adoption of the Dor (or anterior) fundoplication. Investigators have compared the 2 in reference to dysphagia and control of gastroesophageal reflux and have found that the Dor fundoplication is associated with good long-term control of gastroesophageal reflux and less dysphagia than a Nissen fundoplication.⁵⁶ Furthermore, a prospective, randomized clinical trial of myotomy with and without Dor fundoplication showed that patients with the Dor procedure had much less gastroesophageal reflux assessed by 24-hour esophageal pH testing than those without the fundoplication (9% vs 48%). Despite the theoretical concerns, dysphagia was not a long-term complication in either group.⁵⁷

New Treatments

The utility of self-expanding, 30-mm metallic stents for achalasia has been prospectively evaluated in 75 patients with achalasia at a single center over a 13-year period. The clinical success rate after 10 years of follow-up after the stent was removed was high (83%). There were no perforations or mortality associated with the treatment, but stent migration occurred in 5% of patients, reflux in 20% and chest pain in 38.7%.⁵⁸

Several centers are developing esophagomyotomy that is performed via the intestinal lumen. Pasricha et al reported a submucosal esophagomyotomy successfully performed on porcine models endoscopically.⁵⁹ Recently, ≥ 2 groups of investigators have performed peroral endoscopic myotomy. One group published its experience in 17 patients, all of whom had good clinical response with no significant complications in short-term follow-up.^{60,61}

Treatment Recommendations

The appropriate treatment for any given patient with achalasia depends on their willingness to undergo invasive procedures and on their physical ability to endure them. The perforation rate for endoscopic pneumatic dilation with a rigid balloon is approximately 2%. A systematic review of the results of 3086 patients who underwent a laparoscopic myotomy found that complications were reported in 6% and death in 0.1%.⁴⁴ When comparing the overall complication rates of laparoscopic myotomy with dilation, differences are likely related to

the more invasive nature of the laparoscopic procedure, but differences in baseline patient characteristics and severity of the disease may have an impact on the results of each method reported.

A decision analysis model has been pursued for the treatment of achalasia. They evaluated 4 strategies: (1) Laparoscopic Heller myotomy and partial fundoplication, (2) pneumatic dilation, (3) botulinum toxin injection, and (4) thoracoscopic Heller myotomy. Based on complications, need for repeated procedures, and overall treatment cost, they found that laparoscopic Heller myotomy with fundoplication was preferred treatment strategy unless the patient's risk of operative mortality was >0.7%.⁶²

These authors recommend that those patients who meet criteria for achalasia (manometric, endoscopic, radiographic) and who are good surgical candidates should be referred to an experienced center for minimally invasive modified Heller myotomy. Patients who are not good surgical candidates and cannot accept the risk of pneumatic dilation can be treated with endoscopically directed botulinum toxin injection or medications.

Outcomes

Patients who have had treatment for achalasia typically have their response measured by amelioration of their symptoms. Others suggest, however, that there should be more objective testing for response. Manometrically, an LES pressure <10 mm Hg has been shown to be an accurate indicator of a complete myotomy.⁶³ Routine barium esophagram has been demonstrated to have poor positive predictive value postmyotomy;⁶⁴ however, the use of timed barium study to assess esophageal emptying correlates well with clinical outcome after myotomy.⁶⁵ Some authors have voiced concern that some patients may progress to advanced stages of achalasia with minimal symptoms until they present with a megaesophagus. Once this stage is reached, complete esophagectomy may be required, although myotomy is attempted initially. As a result, periodic timed barium swallows may be employed in patients after treatment.⁶⁶

Several studies have reported long-term outcomes. Overall, there is no difference in life expectancy or mortality in patients with treated achalasia versus the general population.⁶⁷ Two decades after an esophagomyotomy and anterior fundoplication is performed, there is eventual evidence of clinical deterioration after initial good results owing primarily to an increase in acid reflux and its associated complications.⁶⁸ Symptoms may recur also owing to either initial incomplete myotomy, regrowth of muscle fibers, or stricturing. Finally, there is clear evidence that achalasia patients (treated or untreated) are at increased risk for esophageal squamous cell carcinoma.⁴⁷ Although there is no consensus on screening we recom-

mend an endoscopy at least once in the decade following the diagnosis of achalasia.

Conclusion

Achalasia is a rare disorder with a possible viral-mediated, autoimmune etiology. When it is diagnosed, it should be treated and the best treatments available are aimed at disrupting the LES either with endoscopic dilation or surgically. Further study is required to determine the cause of achalasia with identifying mechanisms that would facilitate medical intervention. In the near future, we anticipate increased experience with and evaluation of less invasive intraluminal myotomy.

Supplementary Material

The first 5 references associated with this article are available below in print. The remaining references accompanying this article are available online only with the electronic version of the article. To access the remaining references, visit the online version of *Gastroenterology* at www.gastrojournal.org, and at [doi:10.1053/j.gastro.2010.06.024](https://doi.org/10.1053/j.gastro.2010.06.024).

References

1. Birgisson S, Richter JE. Achalasia in Iceland, 1952–2002: an epidemiologic study. *Dig Dis Sci* 2007;52:1855–1860.
2. Mayberry JF, Atkinson M. Variations in the prevalence of achalasia in Great Britain and Ireland: an epidemiological study based on hospital admissions. *Q J Med* 1987;62:67–74.
3. Arber N, Grossman A, Lurie B, et al. Epidemiology of achalasia in central Israel. Rarity of esophageal cancer. *Dig Dis Sci* 1993;38:1920–1925.
4. Mayberry JF, Atkinson M. Incidence of achalasia in New Zealand, 1980–1984. An epidemiological study based on hospital discharges. *J Gastroenterol Hepatol* 1988;3:247–257.
5. Stein CM, Gelfand M, Taylor HG. Achalasia in Zimbabwean blacks. *S Afr Med J* 1985;67:261–262.

Reprint requests

Address requests for reprints to: David A. Katzka, MD, Division of Gastroenterology and Hepatology, Mayo Clinic, 200 First Avenue SW, Rochester, Minnesota 55905. e-mail: katzka.david@mayo.edu; fax: (507) 266-9081.

Conflicts of interest

The authors disclose no conflicts.

References (Online Only)

6. Mayberry JF, Mayell MJ. Epidemiological study of achalasia in children. *Gut* 1988;29:90–93.
7. Sonnenberg A. Hospitalization for achalasia in the United States 1997–2006. *Dig Dis Sci* 2009;54:1680–1685.
8. Stein DT, Knauer CM. Achalasia in monozygotic twins. *Dig Dis Sci* 1982;27:636–640.
9. Clark SB, Rice TW, Tubbs RR, et al. The nature of the myenteric infiltrate in achalasia: an immunohistochemical analysis. *Am J Surg Pathol* 2000;24:1153–1158.
10. Park W, Vaezi MF. Etiology and pathogenesis of achalasia: the current understanding. *Am J Gastroenterol* 2005;100:1404–1414.
11. Wong RK, Maydonovitch CL, Metz SJ, et al. Significant DQw1 association in achalasia. *Dig Dis Sci* 1989;34:349–352.
12. Ruiz-de-Leon A, Mendoza J, Sevilla-Mantilla C, et al. Myenteric antiplexus antibodies and class II HLA in achalasia. *Dig Dis Sci* 2002;47:15–19.
13. Santiago JL, Martinez A, Benito MS, et al. Gender-specific association of the PTPN22 C1858T polymorphism with achalasia. *Hum Immunol* 2007;68:867–870.
14. Paladini F, Cocco E, Cascino I, et al. Age-dependent association of idiopathic achalasia with vasoactive intestinal peptide receptor 1 gene. *Neurogastroenterol Motil* 2009;21:597–602.
15. Facco M, Brun P, Baesso I, et al. T cells in the myenteric plexus of achalasia patients show a skewed TCR repertoire and react to HSV-1 antigens. *Am J Gastroenterol* 2008;103:1598–1609.
16. Kraichely RE, Farrugia G, Pittock SJ, et al. Neural autoantibody profile of primary achalasia. *Dig Dis Sci* ;55:307–311.
17. Gockel I, Bohl JR, Eckardt VF, et al. Reduction of interstitial cells of Cajal (ICC) associated with neuronal nitric oxide synthase (n-NOS) in patients with achalasia. *Am J Gastroenterol* 2008;103:856–864.
18. Goin JC, Sterin-Borda L, Bilder CR, et al. Functional implications of circulating muscarinic cholinergic receptor autoantibodies in chagasic patients with achalasia. *Gastroenterology* 1999;117:798–805.
19. Stylopoulos N, Bunker CJ, Rattner DW. Development of achalasia secondary to laparoscopic Nissen fundoplication. *J Gastrointest Surg* 2002;6:368–376.
20. Jomni T, Dray X, Merrouche M, et al. [Achalasia in an obese woman treated by laparoscopic gastric banding]. *Gastroenterol Clin Biol* 2008;32:973–975.
21. Eckardt VF, Kohne U, Junginger T, et al. Risk factors for diagnostic delay in achalasia. *Dig Dis Sci* 1997;42:580–585.
22. Richter JE. Oesophageal motility disorders. *Lancet* 2001;358:823–828.
23. Hart P, Francis D. Barium esophagram remains a highly sensitive screening examination for the diagnosis of achalasia. *Am J Gastroenterol* 2009;104(suppl 3):3.
24. Howard PJ, Maher L, Pryde A, et al. Five year prospective study of the incidence, clinical features, and diagnosis of achalasia in Edinburgh. *Gut* 1992;33:1011–1015.
25. Pandolfino JE, Kahrilas PJ. AGA technical review on the clinical use of esophageal manometry. *Gastroenterology* 2005;128:209–224.
26. Fisichella PM, Raz D, Palazzo F, et al. Clinical, radiological, and manometric profile in 145 patients with untreated achalasia. *World J Surg* 2008;32:1974–1979.
27. Agrawal A, Hila A, Tutuian R, et al. Manometry and impedance characteristics of achalasia. Facts and myths. *J Clin Gastroenterol* 2008;42:266–270.
28. Hirano I, Tatum RP, Shi G, et al. Manometric heterogeneity in patients with idiopathic achalasia. *Gastroenterology* 2001;120:789–798.
29. Gelfond M, Rozen P, Gilat T. Isosorbide dinitrate and nifedipine treatment of achalasia: a clinical, manometric and radionuclide evaluation. *Gastroenterology* 1982;83:963–969.
30. Coccia G, Bortolotti M, Michetti P, et al. Return of esophageal peristalsis after nifedipine therapy in patients with idiopathic esophageal achalasia. *Am J Gastroenterol* 1992;87:1705–1708.
31. Bortolotti M, Mari C, Lopilato C, et al. Effects of sildenafil on esophageal motility of patients with idiopathic achalasia. *Gastroenterology* 2000;118:253–257.
32. Pasricha PJ, Ravich WJ, Hendrix TR, et al. Treatment of achalasia with intrasphincteric injection of botulinum toxin. A pilot trial. *Ann Intern Med* 1994;121:590–591.
33. Pasricha PJ, Ravich WJ, Hendrix TR, et al. Intrasphincteric botulinum toxin for the treatment of achalasia. *N Engl J Med* 1995;332:774–778.
34. Annese V, D'Onofrio V, Andriulli A. Botulinum toxin in long-term therapy for achalasia. *Ann Intern Med* 1998;128:696.
35. Pasricha PJ, Rai R, Ravich WJ, et al. Botulinum toxin for achalasia: long-term outcome and predictors of response. *Gastroenterology* 1996;110:1410–1415.
36. Smith CD, Stival A, Howell DL, et al. Endoscopic therapy for achalasia before Heller myotomy results in worse outcomes than Heller myotomy alone. *Ann Surg* 2006;243:579–584.
37. Kadakia SC, Wong RK. Graded pneumatic dilation using Rigiflex achalasia dilators in patients with primary esophageal achalasia. *Am J Gastroenterol* 1993;88:34–38.
38. Hulselms M, Vanuytsel T, Degreef T, et al. Long-term outcome of pneumatic dilation in the treatment of achalasia. *Clin Gastroenterol Hepatol* 2010;8:30–35.
39. Chuah SK, Hu TH, Wu KL, et al. Clinical remission in endoscope-guided pneumatic dilation for the treatment of esophageal achalasia: 7-year follow-up results of a prospective investigation. *J Gastrointest Surg* 2009;13:862–867.
40. Reynolds JC, Parkman HP. Achalasia. *Gastroenterol Clin North Am* 1989;18:223–255.
41. West RL, Hirsch DP, Bartelsman JF, et al. Long term results of pneumatic dilation in achalasia followed for more than 5 years. *Am J Gastroenterol* 2002;97:1346–1351.
42. Sanchez-Pernaute A, Aguirre EP, Talavera P, et al. Laparoscopic approach to esophageal perforation secondary to pneumatic dilation for achalasia. *Surg Endosc* 2009;23:1106–1109.
43. Leyden JE, Moss AC, MacMathuna P. Endoscopic pneumatic dilation versus botulinum toxin injection in the management of primary achalasia. *Cochrane Database Syst Rev* 2006:CD005046.
44. Campos GM, Vittinghoff E, Rabl C, et al. Endoscopic and surgical treatments for achalasia: a systematic review and meta-analysis. *Ann Surg* 2009;249:45–57.
45. Csendes A, Braghetto I, Henriquez A, et al. Late results of a prospective randomised study comparing forceful dilatation and oesophagomyotomy in patients with achalasia. *Gut* 1989;30:299–304.
46. Vela MF, Richter JE, Khandwala F, et al. The long-term efficacy of pneumatic dilatation and Heller myotomy for the treatment of achalasia. *Clin Gastroenterol Hepatol* 2006;4:580–587.
47. Zaninotto G, Rizzetto C, Zambon P, et al. Long-term outcome and risk of oesophageal cancer after surgery for achalasia. *Br J Surg* 2008;95:1488–1494.
48. Rosen MJ, Novitsky YW, Cobb WS, et al. Laparoscopic Heller myotomy for achalasia in 101 patients: can successful symptomatic outcomes be predicted? *Surg Innov* 2007;14:177–183.
49. Melvin WS, Needleman BJ, Krause KR, et al. Computer-assisted robotic Heller myotomy: initial case report. *J Laparoendosc Adv Surg Tech A* 2001;11:251–253.
50. Malthaner RA, Tood TR, Miller L, et al. Long-term results in surgically managed esophageal achalasia. *Ann Thorac Surg* 1994;58:1343–1346.

51. Kilic A, Schuchert MJ, Pennathur A, et al. Long-term outcomes of laparoscopic Heller myotomy for achalasia. *Surgery* 2009;146:826–831.
52. Wang YR, Dempsey DT, Friedenberg FK, et al. Trends of Heller myotomy hospitalizations for achalasia in the United States, 1993–2005: effect of surgery volume on perioperative outcomes. *Am J Gastroenterol* 2008;103:2454–2464.
53. Eldaif SM, Mutrie CJ, Rutledge WC, et al. The risk of esophageal resection after esophagomyotomy for achalasia. *Ann Thorac Surg* 2009;87:1558–1562.
54. Scott PD, Harold KL, Heniford BT, et al. Results of laparoscopic Heller myotomy for extreme megaesophagus: an alternative to esophagectomy. *Surg Laparosc Endosc Percutan Tech* 2009;19:198–200.
55. Torquati A, Lutfi R, Khaitan L, et al. Heller myotomy vs Heller myotomy plus Dor fundoplication: cost-utility analysis of a randomized trial. *Surg Endosc* 2006;20:389–393.
56. Rebecchi F, Giaccone C, Farinella E, et al. Randomized controlled trial of laparoscopic Heller myotomy plus Dor fundoplication versus Nissen fundoplication for achalasia: long-term results. *Ann Surg* 2008;248:1023–1030.
57. Richards WO, Torquati A, Holzman MD, et al. Heller myotomy versus Heller myotomy with Dor fundoplication for achalasia: a prospective randomized double-blind clinical trial. *Ann Surg* 2004;240:405–412.
58. Zhao JG, Li YD, Cheng YS, et al. Long-term safety and outcome of a temporary self-expanding metallic stent for achalasia: a prospective study with a 13-year single-center experience. *Eur Radiol* 2009;19:1973–1980.
59. Pasricha PJ, Hawari R, Ahmed I, et al. Submucosal endoscopic esophageal myotomy: a novel experimental approach for the treatment of achalasia. *Endoscopy* 2007;39:761–764.
60. Savides T, Horgan S. Experience with peroral endoscopic myotomy in two patients with achalasia.
61. Inoue H, Minami H, Kobayashi Y, et al. Peroral endoscopic myotomy (POEM) for esophageal achalasia. *Endoscopy*;42:265–271.
62. Urbach DR, Hansen PD, Khajanchee YS, et al. A decision analysis of the optimal initial approach to achalasia: laparoscopic Heller myotomy with partial fundoplication, thoracoscopic Heller myotomy, pneumatic dilatation, or botulinum toxin injection. *J Gastrointest Surg* 2001;5:192–205.
63. Eckardt VF, Aignherr C, Bernhard G. Predictors of outcome in patients with achalasia treated by pneumatic dilation. *Gastroenterology* 1992;103:1732–1738.
64. Melman L, Quinlan JA, Hall BL, et al. Clinical utility of routine barium esophagram after laparoscopic anterior esophageal myotomy for achalasia. *Surg Endosc* 2009;23:606–610.
65. Oezcelik A, Hagen JA, Halls JM, et al. An improved method of assessing esophageal emptying using the timed barium study following surgical myotomy for achalasia. *J Gastrointest Surg* 2009;13:14–18.
66. Vaezi MF, Baker ME, Achkar E, et al. Timed barium oesophagram: better predictor of long term success after pneumatic dilation in achalasia than symptom assessment. *Gut* 2002;50:765–770.
67. Eckardt VF, Hoischen T, Bernhard G. Life expectancy, complications, and causes of death in patients with achalasia: results of a 33-year follow-up investigation. *Eur J Gastroenterol Hepatol* 2008;20:956–960.
68. Csendes A, Braghetto I, Burdiles P, et al. Very late results of esophagomyotomy for patients with achalasia: clinical, endoscopic, histologic, manometric and acid reflux studies in 67 patients for a mean follow-up of 190 months. *Ann Surg* 2007;245:334–335.