

Crohn's Fistula: Current Concepts in Management

DANIEL H. PRESENT

Mount Sinai School of Medicine, New York, New York

Crohn's disease was described in 1932 in the classic article by Crohn et al., and then subsequently the authors described one of the disease complications, namely perianal fistula. It was originally thought that the perianal disease originated in the inflamed terminal ileum, which extended internally down to the perianal area. In the last 70 years, we have learned much about this disease, as well as the complications of both perianal and internal fistula. Approximately 60%–70% of all patients with Crohn's disease will eventually need to undergo surgery, which in many cases is related to the development of a perianal fistula, subsequent to an abscess.¹ The purpose of this article is to review our current knowledge of Crohn's fistula, focusing predominantly on the concepts in clinical management.

Incidence and Pathogenesis

The reported incidence in patients with Crohn's disease ranges from as low as 17% up to close to 50%.² Fistulization is easily recognized when it is in the perianal area; however, in a series in which one third of all patients had fistula approximately half were enteroenteric.³

A recent population-based study reported that fistulas occurred in up to 35% of patients with Crohn's disease with perianal fistulas occurring in 20%.⁴ A cumulative incidence of fistulizing Crohn's was 33% after 10 years and 50% after 20 years. Recurrent fistulas were uncommon in that 66% of patients had only 1 fistula episode. Although the numbers were small, it was of interest to note that recurrent fistula occurred less frequently in patients who were placed on maintenance therapy with an immunosuppressive agent.

Perianal fistula may be the initial presentation of Crohn's disease occurring in up to 10% of patients and may precede the onset of disease by several years.⁵ It has been clearly observed that patients with colonic disease have a higher incidence of perianal fistulas, especially with involvement of the rectum.

Internal fistula may be divided into 2 types: those in which there are internal connections between intestinal structures, such as ileoileal, ileal sigmoid, and gastrocolic, and those that occur between the intestine and

other organs, such as an enterovesical or abdominal wall fistula.⁶ Internal fistula may be present without any symptomatology; however, internal fistulizing disease is believed by many to be more aggressive and requiring frequent and urgent surgical intervention. In a surgical study of 101 patients looking at the cumulative probability requiring repeat surgical intervention, the only statistically significant effect was that of being perforating (fistulizing) compared with nonperforating Crohn's disease.⁷ The median interval between the first and second operation in the fistulizing group was 1.7 years, whereas it was 13 years for the nonfistulizing group.

In regards to pathogenesis, it is now quite clear that the fistulas in the perianal area do not arise from the small intestine, but rather develop locally, either as deep penetrating ulcers in the anus or rectum or secondary to an anal gland abscess.

There are various classification schemes for describing perianal fistula, which are most helpful in the surgical management period.⁸ These include simple low transphincteric, intersphincteric, and superficial fistula, which can be treated with fistulotomy compared with complex and high transphincteric, supersphincteric, or extrasphincteric fistula. As noted, surgical management will depend on the site of the fistulization.⁹

Diagnosis

Multiple abnormalities can occur in the perianal area in addition to Crohn's fistula. The development of large anal tags (often referred to as "elephant ears") is a clue that Crohn's disease is present, especially when associated with gastrointestinal symptoms. Fistulas may hide between these large folds. Patients may also suffer from fissures that tend to involve the squamous lining of the anal canal and are usually very painful in contrast to the relatively painless large anal tags. Confusion with a Bartholin's abscess can occur if gynecologists are not

Abbreviations used in this paper: EUA, examination under anesthesia; EUS, endoscopic ultrasound; MP, mercaptopurine; MRI, magnetic resonance imaging.

© 2003 by the American Gastroenterological Association
0016-5085/03/\$30.00

doi:10.1016/S0016-5085(03)00392-5

aware that the patient has Crohn's disease. After incision by a gynecologist, persistence of drainage will often lead to the correct diagnosis. Patients with small rectovaginal fistulas may not volunteer the fact that they are intermittently passing air through the vagina. The development of large amounts of vaginal fecal material will once again provide a correct diagnosis. It is often difficult to identify the site of a rectovaginal fistula when the patient is examined by either the gynecologist or the gastroenterologist. The majority of fistulas are usually small and derive from the distal portion of the rectovaginal septum. If no bowel disease is evident and the patient has perianal fistula, one should also consider in the differential diagnosis actinomycosis, tuberculosis, or trauma.

For a more precise diagnosis, examination under anesthesia (EUA) has been considered the gold standard for assessing fistulas. This entails a general anesthetic in the operating room using direct digital examination and inserting probes into fistulous tracts. More recently, other techniques have been advised and may include imaging using fistulograms and pelvic computed tomography scans. These techniques have not been considered sufficiently accurate to be clinically useful. A recent prospective triple-blinded study was carried out to assess the accuracy of rectal endoscopic ultrasound (EUS) with pelvic magnetic resonance imaging (MRI) with the prior noted examination under anesthesia.¹⁰ Although the study was small, consisting of 34 patients, the authors found that the accuracy of rectal EUS, pelvic MRI, and surgical EUA all exceeded 85% compared with a consensus gold standard. When any 2 of the diagnostic modalities were combined, the accuracy then increased to 100%. The authors concluded that all 3 techniques were reasonably accurate in classifying perianal disease, but depending on the local expertise available, there should be a combination of either MRI or EUS with surgical evaluation (EUA).

Surgical Management

The vast majority of patients with perianal fistula present with an abscess, which either drains spontaneously or must be drained surgically. Close cooperation is required between gastroenterologist and surgeon in the medical and surgical management of patients with fistula. Over the years, there have been both aggressive approaches or more conservative surgical management with a reliance on medical therapy. In 1 study, incision and drainage alone avoided fistulotomy in more than half of the patients.¹¹ Likewise, an ultraconservative viewpoint has been questioned, citing the fact that this approach may ultimately lead to requirement of resection

and/or stoma.^{12,13} In the recently published community study, surgery was required in 83% of the patients, although in most instances this was minor, whereas 23% of patients required a bowel resection.⁴

If the patient has an abscess that is not drained, a simple incision and drainage is usually effective in superficial abscesses. However, in deeper abscesses, drainage is often required, either with a mushroom catheter or a noncutting seton. The latter will allow for decreased pain and discomfort, as well as an opportunity to treat medically. Temporary ostomy has often been advised in patients who have active perianal, as well as active bowel Crohn's disease.¹⁴ It has been suggested that bypass will allow the patient to heal. Several studies in the literature, as well as my own personal experience, indicate that diversion therapy is effective at best for only a short term, and in the long run proctectomy will be required. Availability of newer therapeutic agents should make temporary ostomy a rarely performed procedure. However, if all currently available medications are ineffective, then proctectomy may be required to restore an adequate quality of life.

Medical Therapy

Mesalamine

Multiple trials have been conducted using sulfasalazine or mesalamine in the treatment of Crohn's disease. Although these agents have not been approved by the Food and Drug Administration for the treatment of Crohn's disease, several studies have shown efficacy with high doses (3 g or more). Despite these multiple studies, there is no mention made of the efficacy of mesalamine agents in the treatment of either internal or external fistula. For the most part, these agents are maintained, even if the patient develops a fistula predominantly for the management of the active bowel disease.

Corticosteroids

Neither the National Cooperative Crohn's Disease nor the European Cooperative Crohn's Disease study randomized patients for fistula, and, therefore, there are no data available to look at clinical response in this subgroup of patients.¹⁵ A new steroid, budesonide, which has been studied and shown to be effective in Crohn's disease, excluded all patients with fistula from the placebo-controlled trials. The only deaths that occurred in the 2 steroid placebo-controlled trials were in patients who had fistula and who developed an internal abscess and overwhelming infection. It has been my personal experience to observe that when patients with

internal fistula are treated with steroids, a small percentage will go on to develop abscess and require urgent surgical intervention. Our studies in patients with enterovesical fistula have shown a significant failure to heal in those patients who are concurrently taking steroids.¹⁶ In summary, corticosteroids should not be used in the treatment of Crohn's disease in patients who have either internal or external fistula.

Antibiotics

There have been several control trials performed to evaluate the efficacy of metronidazole in the treatment of Crohn's disease; however, in neither the Ursing nor Sutherland study, which showed some efficacy in clinical parameters, was there any mention of fistula response.^{17,18} However, in an uncontrolled study by Bernstein et al.¹⁹ evaluating 21 patients with fistula an initial clinical response was observed in 20 of 21. As patients were maintained on metronidazole, complete healing occurred in 10 of 18. A follow-up article in those patients who were treated for more than 3 months showed that relapse frequently occurred (in 6 of 6 patients who lowered the dose relapse was observed), but patients often responded to reinstitution of the metronidazole. Only 5 of 18 patients could successfully discontinue the metronidazole without relapse. Several other studies have confirmed this initial finding, but thus far, there have been no control trials completed showing short- or long-term efficacy of metronidazole for fistula. In addition, a high number of patients have difficulty tolerating the agent, which produces nausea, fatigue, and peripheral neuropathy. Neuropathy is rarely encountered if the dose of metronidazole is maintained at 750 mg daily or less. Likewise, alcohol can be ingested in well over 90% of patients without any Antabuse (Odyssey Pharmaceuticals, Inc., East Hanover, NJ) reaction.

Because of the high toxicity profile of the metronidazole, there have been several studies evaluating ciprofloxacin in the treatment of active Crohn's disease. Colombel et al.²⁰ studied mesalamine versus Cipro (Bayer Corp., West Haven, CT) in a control trial and showed 56% complete remission with the latter compared with 55% remission with mesalamine. Fistula were not evaluated in this study; however, Turunen et al.²¹ in an uncontrolled study of 10 patients with fistula showed that there was a response of 70% to 1 to 1.5 g Cipro for 3 months. Recurrences of fistula were frequent but often responded to restarting the ciprofloxacin. Surgical excision was required in several cases. Solomon²² performed a retrospective analysis of the combination of Cipro and metronidazole in 14 patients with perianal disease that revealed that 3 patients healed completely and 85% of

patients improved. Although no control trials have been performed using ciprofloxacin in fistulizing Crohn's, a current study is underway to answer some of these questions.

It is my experience that antibiotics are effective in perianal disease, usually without complete healing; however, they may maintain comfort and improved quality of life for long periods of time. I have observed response with the chronic use of Cipro for 1 year or greater, and attempts to withdraw the agent have resulted in exacerbation of perianal disease.

6 Mercaptopurine/Azathioprine

The first control trial to evaluate for fistula response in patients with Crohn's disease was a randomized double-blind study of 6 mercaptopurine (6 MP) versus placebo in unresponsive disease.²³ The duration of the study was 2 years with a crossover after 1 year. A clinical response with steroid sparing was seen in approximately two thirds of patients, and 9 of 29 (31%) patients who received 6 MP closed their fistulas. In the placebo group only 1 of 17 (6%) closed their fistula. Additional healing was observed in 34% with 6 MP compared with 18% with placebo. These data were not statistically significant because of the small numbers; however, there was a clear trend toward healing with 6 MP. The data were further expanded in an uncontrolled manner that showed complete closure in 39% of patients using 6 MP with a partial response in 26% and no response in 35%.²⁴ Patients were slow to respond to this medication, which took 2 to 4 months to be effective, with the longest time to respond being 8 months. In looking at 13 patients whose fistulas closed completely, in 6 of 13 who remained on the drug, the fistula continued to be closed, whereas, of 7 patients who stopped the drug, only 2 remained closed and 5 reopened.

A subsequent meta-analysis reported that 22 of 41 (54%) patients treated with 6 MP/azathioprine responded versus only 6 of 29 (21%) treated with placebo.²⁵ The pooled odds ratio favoring fistula healing was 4.44.

It is quite clear that 6 MP/azathioprine is effective, both in closing and maintaining closure of fistula. In addition, these drugs have shown significant long-term safety without any evidence of development of neoplasia or super infections. The majority of toxicity occurs early in the course with allergic rash, fever, or pancreatitis. A small percentage of patients who are thiopurine methyltransferase deficient also may develop leukopenia. Close monitoring of the white blood cell count will prevent this complication. There appears to be little question

that 6 MP/azathioprine is the initial drug of choice to try and close perianal fistula.

Methotrexate

There have been several controlled, as well as uncontrolled, studies looking at the efficacy of methotrexate in the treatment of Crohn's disease. Although showing efficacy in reducing and maintaining remission, fistula were not evaluated. In a small study of 37 courses of methotrexate, 62% had a clinical response to therapy. Sixteen patients had fistulizing disease, and 4 (25%) had complete closure of fistulas, whereas 5 (31%) had partial response.²⁶ Therefore, the overall rate of fistula response was 9 of 16 (56%). Several of these patients did not respond to cyclosporin A and/or 6 MP. With the limited available data, it would appear that 6 MP/azathioprine is the first choice for the management of perianal fistula; however, if patients do not respond or are allergic, methotrexate in a dose of 25 mg intramuscularly on a weekly basis should be tried. The toxicity of methotrexate is well known (hepatic fibrosis, pneumonitis, gastrointestinal upset, etc.); however, the main contraindication would be if the patient is planning conception in the near future because of known toxicity to the fetus.

Cyclosporin A

Cyclosporin A has shown variable efficacy in the treatment of Crohn's disease. The initial studies showed that higher doses were effective; however, when an oral dose of 5 mg/kg daily or less is used no benefit has been observed in either treating active disease or maintaining remission. Administration of the drug intravenously in a dose of 4 mg/kg has shown efficacy not only in clinical response but also in the management of fistula. In our own personal series 14 of 16 patients (88%) responded to the acute intravenous treatment. Complete closure of fistula was observed in 7 (44%), and a moderate improvement was observed in the remaining 7 (44%).²⁷ The mean time to respond was slightly over 7 days, and all patients received therapeutic cyclosporin A levels during the intravenous phase. We usually tried to obtain a monoclonal level of 3–400 ng/mL. Response was observed in 9 of 10 patients who had failed 6 MP/azathioprine. After discharge, 5 of 14 (36%) relapsed to some degree, but 64% maintained their improvement. In addition, steroids could be discontinued. Thus far, there are 10 uncontrolled studies in the literature and the overall initial response is 83%.

There is no question that cyclosporin A is dramatically effective in the treatment of fistula, as well as active Crohn's disease. Significant toxicity can be observed with higher doses, and physicians should have expertise in

using this agent. Likewise, cyclosporin A often will not maintain response long term; therefore, all patients should be treated with concurrent 6 MP/azathioprine on discharge for maintenance. If the patient is allergic to 6 MP/azathioprine, we try and maintain the cyclosporin A response with parenteral methotrexate.

Tacrolimus (FK506)

Several small series have been published on the use of Tacrolimus (Fujisawa Healthcare, Inc., Deerfield, IL) in Crohn's patients with fistula.^{28,29} Improvement was observed in all 11 patients treated with a dose ranging from 0.15–0.31 mg/kg per day. Seven of the 11 closed their fistula completely. More recently, a study has been completed looking at the efficacy of Tacrolimus in the treatment of Crohn's perianal fistula. This was a placebo-controlled trial and showed statistically significant efficacy; however, nephrotoxicity was quite high, precluding the routine use of this agent.³⁰ Combinations of lower-dose oral Tacrolimus in combination with other agents requires future studies.

Infliximab and Other Anti-Tumor Necrosis Factor α Agents

Infliximab is a chimeric monoclonal antibody that has shown efficacy in the treatment of chronically active Crohn's disease. This antibody, which binds to tumor necrosis factor α , was shown in preliminary efficacy studies to also positively affect perianal fistulization. Twelve centers in the United States and Europe then participated in a randomized double-blind placebo-controlled trial in which patients received 3 infusions of either 5 mg/kg or 10 mg/kg Infliximab (Centocor, Inc., Malvern, PA) versus placebo.³¹ Infusions were given at week 0, 2, and 6, and 94 patients were enrolled in this trial. The primary endpoint was a reduction in the number of draining fistulas of 50% or more on 2 consecutive visits. Fistulas were considered closed if they were no longer draining despite gentle finger compression. Several secondary endpoints were also observed, the most important of which was closure of all fistula for at least 2 consecutive visits. At a 5-mg/kg dose, the primary endpoint was achieved in 62% of patients ($P = 0.002$). Of even greater significance was the complete closure of fistula in 46% of patients compared with 13% with placebo ($P = 0.001$). A 5-mg/kg dose was the most effective and closed 55% of all fistula. The vast majority of fistula closed before the third infusion was administered. In observing variables, there were no differences in regards to duration, extent of disease, prior surgery, whether there was 1 or more than 1 fistula, concomitant activity, or for any medication the patient was taking.

Adverse events were similar to those seen in the therapeutic nonfistula trial and included infusion reactions, delayed hypersensitivity reactions (if there was a long duration between infusions), and formation of anti-double-stranded DNA. Rarely was a lupus-like reaction observed. Patients did develop human antichimeric antibodies that in the long run may affect allergic reactions and lack of response. Reactivation of latent tuberculosis has been observed and requires tuberculin testing, as well as chest x-ray to be performed before infusions. A recent user's guide for clinicians has been published.³²

In the initial study, the median duration of response was 3 months for patients who achieved the primary endpoint. A recent long-term study has been reported in abstract in which Infliximab was evaluated for both inductive and maintenance treatment of 306 patients with draining fistula.³³ All patients received a 5-mg/kg infusion at weeks 0, 2, and 6, and those patients who responded to treatment (with a 50% or greater reduction in number of draining fistulas) were then randomized to a maintenance phase. This consisted of either Infliximab 5 mg/kg or placebo every 8 weeks. Sixty-nine percent of patients achieved a fistula response at 14 weeks and were then randomized to the maintenance phase of the study, which showed that Infliximab therapy was more effective than the 3-dose induction alone. Patients who were on maintenance had a significantly longer time to loss of response, higher rates of fistula closure, longer duration of fistula closure, as well as improvement in the Crohn's Disease Activity Index and Inflammatory Bowel Disease Questionnaire.

CDP571, which is a more humanized antibody against tumor necrosis factor α , was studied in a placebo control trial of 167 patients.³⁴ Thirty-seven of the patients had actively draining fistula, and 50% had closure of 50% or more of their fistula compared with 15% placebo response.

Other Therapies

Various agents had been used in uncontrolled studies to try and close fistula. Total parenteral nutrition and the use of elemental diets have been anecdotally reported as showing some response. Bowel rest will rarely close Crohn's fistulas for any prolonged period of time after food is reinstated. Thalidomide has been shown in 2 uncontrolled studies to have some effect on fistulization in Crohn's; however, toxicity precludes the long-term use of this agent in many patients. Hyperbaric oxygenation has also anecdotally been reported as showing success. As with all therapeutic agents, placebo-controlled data must be available before these agents are used in the standard

therapy for Crohn's fistula. Combination therapies will likely be used in the future.³⁵

Internal Fistula

As noted earlier, internal fistulas are usually associated with a more aggressive subtype of Crohn's disease. However, thus far, there have been no placebo-controlled trials looking at the effect of medical therapy on internal fistula healing.⁶ There is somewhat of an ethical issue in that patients will require additional radiation, either through a small bowel series or CT scanning to observe fistula closure. It is also not unusual to perform a small-bowel series and see significant internal fistulization with no clinical manifestations. In fact, ileosigmoidal fistulas may also develop associated with severe narrow terminal ileal disease, and, after the fistula occurs, the obstructive symptoms may be alleviated and patients may show significant clinical improvement.

Obviously, large abscesses should be drained, either percutaneously or surgically, and antibiotics, usually Cipro and metronidazole, should be introduced. Smaller abscesses may respond to drainage and antibiotics; however, surgical intervention is indicated for complicated fistula, especially those accompanied by intestinal obstruction or persistent symptoms with decreased quality of life. Experience has shown that 6 MP/azathioprine may be effective in closing internal fistula. In an uncontrolled study, antibiotics and 6 MP were able to close approximately 40% of enterovesical fistula.³⁶

Rectovaginal fistulas are usually difficult to heal, but medical therapy with antibiotics and immunomodulatory agents may decrease the amount of drainage and improve the quality of life. Surgery is often required for fistulas in which there is moderate drainage of stool from the vagina. Endorectal advancement flaps have been successful in carefully selected patients.³⁷ Although rare, carcinomas can arise in a fistula. A recent report of 7 patients indicated that 4 were squamous cell carcinomas and 3 were adenocarcinomas.³⁸ Carcinomas can be very difficult to diagnose, especially with a flexible sigmoidoscopy. Therefore, examination under anesthesia should be performed periodically to exclude this complication.

There have been a few studies looking at the cost utility of Infliximab in the treatment of Crohn's perianal fistula. In a 1-year study using a Markov model, it was shown that Infliximab was much more expensive than the combination of 6 MP and metronidazole.³⁹ The authors suggested that the incremental benefit of Infliximab in treating Crohn's disease fistula over a 1-year period may not justify the higher cost.

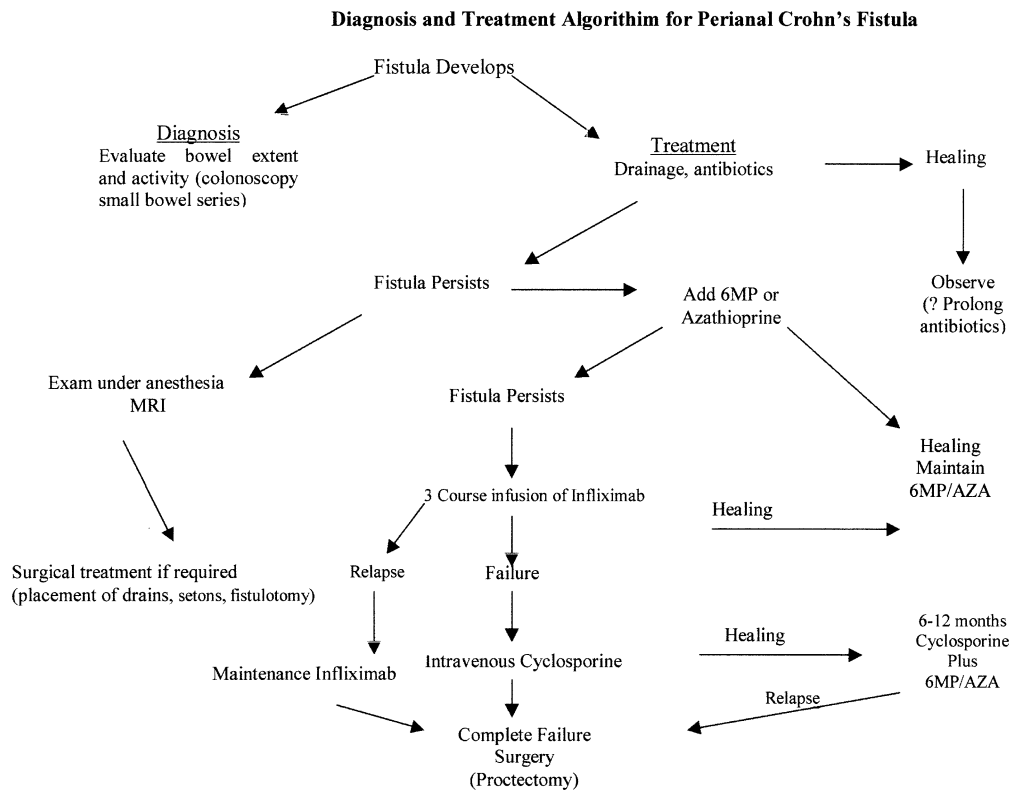


Figure 1. An algorithm is provided that may be helpful in the management of patients with perianal fistula. It must be clearly understood that patients are quite variable and therapy should be individualized, especially as regards quality of life issues.

Management Conclusions

The management of fistulization, both internal and perianal, requires close cooperation between surgeons and gastroenterologists. A recent review has presented a treatment algorithm that will provide guidelines for management (Figure 1).⁹ Pain should always be promptly relieved and abscesses drained preferably by a colorectal surgeon. If a complex fistula or a high fistula appears to be present, then an examination should be performed under anesthesia with an MRI to completely define the extent. Setons can be placed for more extensive fistula to allow medical therapy. Antibiotics are indicated and can either be ciprofloxacin or metronidazole or a combination. I believe for complex fistulas 6 MP/azathioprine should be administered early in the course. I believe it is an error to administer Infiximab until an attempt has been made to heal with the drugs that we have significant long-term experience as to efficacy and safety (e.g., 6 MP/azathioprine). Also, in the placebo-controlled trials, patients appear to respond somewhat better and longer with less allergic reactions when 6 MP/azathioprine or methotrexate were already being administered to the patient. A recent study concluded that concomitant immunosuppressive therapy reduces the magnitude of the immunogenic response to Infiximab.⁴⁰ If 6 MP/azathioprine and/or methotrexate fails then Infiximab should be administered at 0, 2, and 6 or 8 weeks

and will probably be required on a semiregular basis in the future. I do not believe Infiximab should be given chronically every 8 weeks until it has shown that the patient absolutely requires this frequency of administration. There are many patients who require infusions less frequently (every 4 to 6 months), and this can be determined with close follow-up. Cyclosporin A, usually initially administered intravenously in the hospital, is a reasonable choice for those patients who are allergic or fail to respond to Infiximab.

References

1. Glotzer DJ. Surgical therapy for Crohn's disease. *Gastroenterol Clin North Am* 1995;24:577-596.
2. Allan A, Keighley RB. Management of perianal disease. *World J Surg* 1988;12:198-202.
3. Givel JC, Hawker P, Allan R, Alexander-Williams J. Entero-enteric fistula complicating Crohn's disease. *J Clin Gastroenterol* 1983; 5:321-323.
4. Schwartz DA, Loftus EV Jr, Tremaine WJ, Panaccione R, Harmsen WS, Zinsmeister AR, Sandborn WJ. The natural history of fistulizing Crohn's disease in Olmstead County, Minnesota. *Gastroenterology* 2002;122:875-880.
5. Hellers G, Bergstrand O, Ewerth S, Holmstrom B. Occurrence in outcome after primary treatment of anal fistulae in Crohn's disease. *Gut* 1980;21:525-527.
6. D'Haens G. Medical management of internal fistulae in Crohn's disease. *Inflamm Bowel Dis* 2006;6:244-245.
7. Aeberhard P, Berchtold W, Riedtmann HJ, Stadelmann G. Surgical recurrence of perforating and non-perforating Crohn's disease—a study of surgically treated patients. *Dis Colon Rectum* 1996;39: 80-87.

8. Parks AG, Gordon PH, Hardcastle JD. A classification of fistula-in-ano. *Br J Surg* 1976;63:1-12.
9. Schwartz DA, Pemberton JH, Sandborn WJ. Diagnosis and treatment of perianal fistulas in Crohn disease. *Ann Intern Med* 2001; 135:906-918.
10. Schwartz DA, Wiersma MJ, Dudiak KM, Fletcher JG, Clain JE, Tremaine WJ, Zinsmeister AR, Norton ID, Baardman LA, Devine RM, Wolff BG, Young-Fadok TM, Dehl NN, Pemberton JU, Sandborn WJ. A comparison of endoscopic ultrasound, magnetic resonance imaging, and exam under anesthesia for evaluation of Crohn's perianal fistulas. *Gastroenterology* 2001;121:1064-1072.
11. Hamalainen K-PJ, Sainio AP. Incidence of fistulas after drainage of acute anorectal abscesses. *Dis Colon Rectum* 1998;41: 1357-1362.
12. Makowiecs JO, Jehle BC, Becker HD, Starlinger M. Perianal abscess in Crohn's disease. *Dis Colon Rectum* 1997;40:443-450.
13. Sohn N. Selected summaries. *Inflamm Bowel Dis* 1998;4:257.
14. Williams JG, Rothenberger DA, Nemer FD, Goldberg SM. Fistula-in-ano in Crohn's disease with results of aggressive surgical treatment. *Dis Colon Rectum* 1991;34:378-384.
15. Present DH. How to do without steroids in inflammatory bowel disease. *Inflamm Bowel Dis* 2000;6:48-57.
16. Present DH. Urinary tract fistulas in Crohn's disease: surgery versus medical therapy. *Am J Gastroenterol* 2002;97:2165-2167.
17. Ursing B, Kamme C. Metronidazole for Crohn's disease. *Lancet* 1975;1:775-777.
18. Sutherland L, Singleton J, Sessions J, Hanauer S, Krawitt E, Rakin G, Summers R, Mekhjian N, Greenberger N, Kelly M, Levine J, Thomson A, Alpert E, Prokipchu K. Double blind placebo control trial of metronidazole in Crohn's disease. *Gut* 1991;32:1071-1075.
19. Bernstein LH, Frank MS, Brandt LJ, Boley SJ. Healing of perineal Crohn's disease with metronidazole. *Gastroenterology* 1987;79: 357-365.
20. Colombel JF, Lemann M, Cassagnou M, Scuhnik Y, Duclos B, Notteghem B, and the GETAID. A control trial comparing ciprofloxacin with mesalazine for the treatment of active Crohn's disease. *Am J Gastroenterol* 1999;94:674-678.
21. Turunen UM, Farkkila M, Valtone N. Long-term outcome of ciprofloxacin in the treatment of severe perianal or fistulous Crohn's disease. *Gastroenterology* 1993;104A:793 (abstr).
22. Solomon MJ. Combination of ciprofloxacin and metronidazole in severe perianal Crohn's disease. *Can J Gastroenterol* 1993;7: 571-573.
23. Present DH, Korelitz BI, Wisch N, Glass JL, Sachar DG, Pasternack BS. Treatment of Crohn's disease with 6 Mercaptopurine. A long term randomized double blind study. *N Engl J Med* 1980; 302:981-987.
24. Korelitz BI, Present DH. The favorable effects of 6 mercaptopurine in the fistulous Crohn's disease. *Dig Dis Sci* 1985;30:58-64.
25. Pearson DC, May GR, Fick GH, Sutherland LR. Azathioprine and 6 mercaptopurine in Crohn's disease—a meta-analysis. *Ann Intern Med* 1995;123:132-142.
26. Muhadevan U, Marion J, Present DH. The price of methotrexate in the treatment of refractory Crohn's disease. *Gastroenterology* 1997;112A:1031 (abstr).
27. Present DH, Lichtiger S. Efficacy of cyclosporin in the treatment of fistula of Crohn's disease. *Dig Dis Sci* 1994;39:374-380.
28. Lowery PW, Weaver AL, Tremaine WJ, et al. Combination therapy with oral Tacrolimus (FK506) and Azathioprine with 6 Mercaptopurine for treatment refractory Crohn's disease perianal fistula. *Inflamm Bowel Dis* 1999;5:239-245.
29. Sandborn WJ. Preliminary report on the use of oral Tacrolimus (FK506) in the treatment of complicated proximal small bowel and fistulizing Crohn's disease. *Am J Gastroenterol* 1997;92: 876-879.
30. Sandborn WJ, Present DH, Isaacs KL, Wolf DR, Greenberg E, Hanauer SB, Feacan BG, Johnson T, Galanka J, Martin C, Sandler RS. Tacrolimus (FK506) for the treatment of perianal and enterocutaneous fistulas in patients with Crohn's disease: a randomized double blind placebo control trial. *Gastroenterology* 2003; 124: (in press).
31. Present DH, Rutgeerts P, Targan S, Hanauer SB, Mayer L, Van Hogezaand RA, Podolsky DK, Sands BE, Braakman T, DeWoody KL, Schaible TF, Van Deventer SJI. Infliximab for the treatment of fistulas in patients with Crohn's disease. *N Engl J Med* 1999; 340:1398-1405.
32. Sandborn WJ, Hanauer SD. Infliximab in the treatment of Crohn's disease. A user's guide for clinicians. *Am J Gastroenterol* 2002; 97:2962-2972.
33. Sands B, Vandeventer B, Bernstein C, et al. Long-term treatment of fistulizing Crohn's disease: response to Infliximab in the Accent II trial through 54 weeks. *Gastroenterology* 2002;122:A81 (abstr).
34. Sandborn WJ, Feagan SC, Hanauer SB, Present DH, Sutherland LR, Komm MK, Wolf DC, Baker JP, Hawkey C, Archambault N, Bernstein CN, Novak C, Targan SR. An engineered human antibody TΔTNF(CDP 571) for active Crohn's disease: a randomized, double blind, placebo controlled trial. *Gastroenterology* 2001; 120:1330-1338.
35. Ochsenkuhn T, Goke B, Sackmann M. Combining Infliximab with 6 Mercaptopurine/Azathioprine for fistula therapy in Crohn's disease. *Am J Gastroenterol* 2002;97:2022-2025.
36. Wheeler C, Marion JF, Present DH. Medical therapy, not surgery, is the appropriate first line treatment of Crohn's enterovesical fistula (abstr). *Gastroenterology* 1998;114A:1113.
37. Sonoda T, Haul T, Piedmonte MR, Fazi V. Outcomes of primary repair of anorectal and rectovaginal fistulas using the endorectal advancement flap. *Dis Colon Rectum* 2002;45:1622-1628.
38. Ky A, Sohn N, Weinstein MA, Conners Jr AF. Carcinoma arising in anorectal fistulas of Crohn's disease. *Dis Colon Rectum* 1998; 41:992-996.
39. Arsenau KO, Cohn SM, Cominelli F, Korelitz BI. Cost-utility as initial medical management for Crohn's disease perianal fistulae. *Gastroenterology* 2001;120:1640-1656.
40. Baert F, Noman M, Vermeire S, Van Assgie G, D'Haens G, Carbonez A, Rutgeerts P. Influence of immunogenicity on the long term efficacy of Infliximab in Crohn's disease. *N Engl J Med* 2003;348:601-608.

Received February 18, 2003. Accepted March 19, 2003.

Address requests for reprints to: Daniel H. Present, M.D., Mount Sinai School of Medicine, 12 East 86th Street, New York, New York 10028-0517. e-mail: IBD1CENTER@aol.com; fax: (212) 628-3648.