

# Current Diagnosis and Management of Primary Sclerosing Cholangitis

Jens J. W. Tischendorf, Andreas Geier, and Christian Trautwein

Medical Department III (Gastroenterology, Hepatology, and Metabolic Diseases), University Hospital Aachen, Aachen, Germany

Primary sclerosing cholangitis (PSC) is an important liver disease with major morbidity and mortality. The diagnosis of PSC is confirmed by magnetic resonance cholangiopancreatography, and endoscopic retrograde cholangiopancreatography is performed in patients needing therapeutic endoscopy. As a result of the unknown cause of the disease, current medical therapies are unsatisfactory. Nevertheless, high-dose ursodeoxycholic acid should be recommended for treatment of PSC patients because there is a trend toward increased survival. Dominant bile duct stenoses should be treated endoscopically. However, liver transplantation continues to be the only therapeutic option for patients with advanced disease. Estimation of prognosis and timing of liver transplantation should be determined individually for each PSC patient on the basis of all results. The diagnosis and treatment of cholangiocarcinoma (CC) still remain a challenge in PSC patients. Early diagnosis of CC certainly is a prerequisite for successful treatment with surgical resection or innovative strategies such as neoadjuvant radiochemotherapy with subsequent orthotopic liver transplantation. Therefore, endoscopic techniques such as cholangioscopy and/or intraductal ultrasound may be useful diagnostic tools in patients with stenoses suspicious for malignancy. *Liver Transpl* 14:735-746, 2008. © 2008 AASLD.

Received November 8, 2007; accepted January 16, 2008.

Primary sclerosing cholangitis (PSC), first described by Hoffmann in 1867,<sup>1</sup> is a chronic cholestatic liver disease characterized by inflammation and periductal fibrosis of the intrahepatic and/or extrahepatic bile ducts. The concept of PSC as a generalized disorder of both the intrahepatic and extrahepatic biliary tract and the gallbladder was first introduced in 1967 by Thorpe and coworkers.<sup>2</sup> Although the clinical course is very variable, progressive obliteration of the biliary tree leads to biliary cirrhosis and its complications in a significant proportion of patients.<sup>3-5</sup> The most dismal sequel of PSC is the occurrence of hepatobiliary carcinomas, especially cholangiocarcinoma (CC) in 6%-20% of patients.<sup>6-11</sup> Additionally, PSC is closely linked to inflammatory bowel disease (IBD), particularly ulcerative colitis, which is found in approximately two-thirds of patients with PSC.<sup>5,8,9,12</sup> The cause of PSC is unknown. Although often associated with autoantibodies,

PSC is not a typical autoimmune disease and responds poorly to immunosuppressive therapies, if at all. In children, however, the clinical course and treatment of PSC might be different; in particular, the overlap of PSC with autoimmune hepatitis is more often found in children than in adults.<sup>13-15</sup> Currently, liver transplantation remains the only life-extending treatment option for patients with end-stage PSC.<sup>16</sup> Consequently, PSC has become one of the most common causes of chronic liver disease leading to orthotopic liver transplantation (OLT).<sup>17,18</sup>

The present review addresses recent aspects of PSC in adults and focuses on diagnosis and management.

## EPIDEMIOLOGY AND ETIOPATHOGENESIS

Because high-quality epidemiologic studies are difficult to conduct, only 2 population-based epidemiologic

**Abbreviations:** AP, alkaline phosphatase; ASAT, aspartate aminotransferase; CC, cholangiocarcinoma; DB, double blind; ERCP, endoscopic retrograde cholangiopancreatography; HLA, human leukocyte antigen; IBD, inflammatory bowel disease; MRCP, magnetic resonance cholangiopancreatography; n.a., not assessed; OLT, orthotopic liver transplantation; PC, placebo-controlled; PSC, primary sclerosing cholangitis; PTCD, percutaneous transhepatic cholangiodrainage; UDCA, ursodeoxycholic acid.

Address reprint requests to Jens J. W. Tischendorf, M.D., Medical Department III (Gastroenterology, Hepatology, and Metabolic Diseases), University Hospital Aachen, Pauwelsstraße 30, D-52074 Aachen, Germany. Telephone: +49-241-80-80860; FAX: +49-241-80-82455; E-mail: jentischendorf@freenet.de

DOI 10.1002/lt.21456

Published online in Wiley InterScience (www.interscience.wiley.com).

studies from Norway and the United States have been published to date.<sup>19,20</sup> The mean annual incidence rates were between 0.9 and 1.3 cases per 100,000 person years, and the prevalence was between 8.5 and 13.6 cases per 100,000 persons. There is a strong 70% male predominance of affected individuals. The average age at diagnosis is in the fourth decade, but it can range from 1 to 90 years.<sup>21</sup> Comparable data were found in an epidemiological study from the United Kingdom.<sup>22</sup> Additional data on estimates of incidence and prevalence of PSC derive from tertiary academic centers and from extrapolations based on the strong association between PSC and IBD. However, the overall incidence and prevalence of PSC in Spain, Asia, and Alaska were much lower than those observed in the United States, United Kingdom, and Norway, and this might indicate geographical variations.<sup>23-25</sup> The frequency of PSC in Africa is unknown.

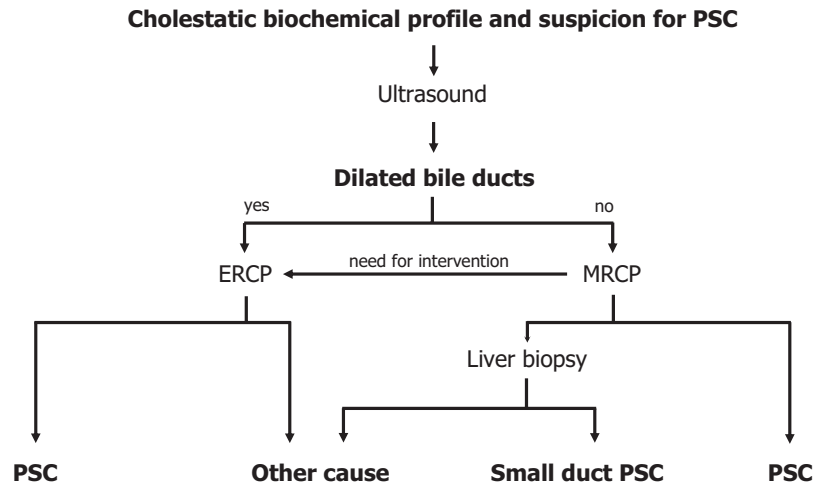
The association between PSC and IBD is well established. Among European and North America populations, an estimated 63% to 90% of PSC patients develop IBD.<sup>5,8-10,12,26,27</sup> In contrast, IBD is found in 54% or less of PSC patients in Spain, Italy, and India and in only 20% of patients with PSC in Asian countries.<sup>23,28-30</sup> The prevalence of PSC in patients with IBD has been reported widely and ranges from 2.4% to 7.5%.<sup>31-35</sup>

PSC is most likely a multifactorial disease, but the exact etiopathology remains unknown so far. However, immunopathogenetic mechanisms are likely involved because an association with human leukocyte antigen (HLA) complex haplotypes, multiple autoantibodies, and the presence of IBD is found in more than 80% of PSC patients.<sup>36,37</sup> A genetic predisposition is shown by the 100-fold increased risk of PSC among siblings.<sup>38</sup> Correspondingly, an increased prevalence of HLA class I A1 as well as HLA class II B8 and DR3 is observed in PSC patients.<sup>39,40</sup> Rapid disease progression in the presence of DR4 has been described but has subsequently been discussed rather controversially.<sup>41,42</sup> A number of non-major histocompatibility class candidate genes may also influence susceptibility or resistance to clinical disease from PSC, such as matrix metalloproteinase-3, tumor necrosis factor  $\alpha$ , and certain cystic fibrosis transmembrane conductance regulator mutations.<sup>43-45</sup> Recently, a "toxic bile" hypothesis has been derived from the PSC-like phenotype in phospholipid flippase Mdr2-deficient mice, indicating that defective biliary phospholipid secretion may cause progressive cholangiocyte injury.<sup>46</sup> However, neither of 2 recent studies in PSC patients found an increase in *MDR3* haplotype distribution in humans.<sup>47,48</sup> Additionally, PSC seems to be a T-helper 1 proinflammatory cytokine-driven disease. Tumor necrosis factor  $\alpha$  and interferon- $\gamma$  stimulate the biliary epithelium to generate nitric oxide via nitric oxide synthase induction, which in turn causes ductular cholestasis.<sup>49</sup> Nitric oxide synthase expression is significantly increased in the biliary epithelium of PSC patients.<sup>50</sup> On the other hand, there are several features that distinguish PSC from a classical autoimmune disease, such as male predilection,

poor response to immunosuppressive therapy, and the absence of disease-specific autoantibodies. Perinuclear, anti-neutrophil cytoplasmatic antibodies were found in up to 88% of PSC patients but did not prove to be specific for this disease.<sup>51,52</sup> The presence of perinuclear, anti-neutrophil cytoplasmatic antibodies is considered to be an epiphenomenon rather than a finding of primary pathogenetic importance.

## CLINICAL PRESENTATION AND DIAGNOSIS

The major diagnostic criteria for PSC are cholangiographic findings of multifocal strictures and beading of the intrahepatic and/or extrahepatic bile ducts with compatible cholestatic biochemical abnormalities after exclusion of secondary causes.<sup>3,21</sup> Currently, up to 45% of PSC patients have been asymptomatic until diagnosis because these cases are defined when a structural biliary abnormality is identified.<sup>5,9,53</sup> Thus, there may be many more unidentified PSC cases in IBD patients who never have had a cholangiogram or a liver biopsy. This is one of the reasons that diagnosis of PSC is made with a mean delay of 4 years from the first presentation of biochemical abnormalities consistent with PSC.<sup>5,9</sup> However, the majority of PSC patients present with symptoms such as abdominal pain, pruritus, jaundice, fatigue, weight loss, and fever; abdominal pain in the right upper quadrant is the most prevalent symptom. The physical examination is usually unremarkable in early stages. If positive, it may disclose hepatomegaly (45%), splenomegaly (30%), skin hyperpigmentation (25%), excoriations (20%), or ascites (1%).<sup>5</sup> Over the past 2 decades, changes in the clinical presentation of PSC patients have been observed, with significantly older age at diagnosis, fewer symptoms at diagnosis, and a lower frequency of coexisting IBD.<sup>54</sup> In a significant proportion of PSC patients, osteopenia is a common complication and seems to be correlated with the stage of the liver disease.<sup>55,56</sup> Although disease-specific laboratory changes do not exist, a cholestatic biochemical profile is frequently found in PSC patients. Elevation of alkaline phosphatase and/or  $\gamma$ -glutamyl transpeptidase occurs in nearly 100% of cases, and a mild to moderate elevation of aminotransferase levels also is usually present.<sup>5</sup> Serum bilirubin levels are normal in 60% of individuals at diagnosis.<sup>3,57</sup> Bilirubin levels fluctuate spontaneously over time, but elevation longer than 3 months may indicate advanced disease or CC.<sup>5</sup> At the time of diagnosis, PSC typically involves both intrahepatic and extrahepatic bile ducts in 69% of patients but is less often restricted to the intrahepatic (25%) or extrahepatic bile ducts (4%) only. A dominant bile duct stenosis is present in up to 35% of patients.<sup>5</sup> An unremarkable cholangiogram is seen in 2% of all patients with typical biochemical and histological features of PSC, and this disease subentity is termed "small-duct PSC".<sup>58-61</sup> Interestingly, the majority of patients with small-duct PSC do not progress to large-duct PSC. This indicates that small-duct PSC might represent a distinct clinical entity rather than an early form of classical PSC. Re-



**Figure 1. Diagnostic algorithm in patients with a cholestatic biochemical profile and suspicion for PSC. Abdominal ultrasound represents the first step in the diagnostic algorithm. Because it is less invasive, MRCP is primarily used for diagnosing PSC in standard patients without dilated bile ducts, whereas ERCP is preferred if dilated bile ducts demonstrate a need for direct intervention. In patients with unremarkable cholangiogram, liver biopsy may detect “small-duct PSC.” Abbreviations: ERCP, endoscopic retrograde cholangiopancreatography; MRCP, magnetic resonance cholangiopancreatography; PSC, primary sclerosing cholangitis.**

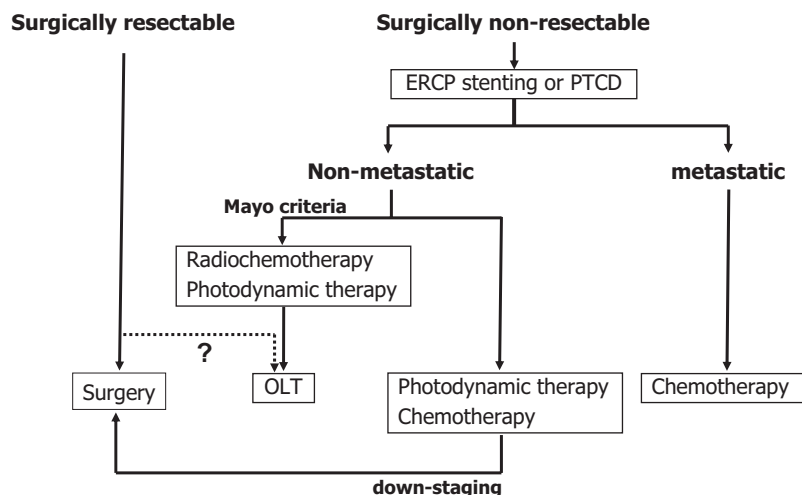
cently, another new disease entity has been described in the literature and named immunoglobulin G4-associated cholangitis; it is characterized as a steroid-responsive biliary disease.<sup>62-64</sup> This entity might represent a distinct subtype of PSC.

Cholangiography, preferably endoscopic retrograde cholangiopancreatography (ERCP), has been the gold standard for visualization of the biliary tract in PSC patients for over 2 decades. Recently, mainly because it is less invasive, magnetic resonance cholangiopancreatography (MRCP) has gained priority for diagnosing PSC. In a prospective comparative study, MRCP had an overall diagnostic accuracy of 90% in detecting the biliary disease versus 97% for ERCP or percutaneous cholangiography.<sup>65</sup> In more recent studies, it could be confirmed that ERCP and MRCP perform equally well in the diagnosis of PSC.<sup>66,67</sup> In contrast to ERCP, MRCP provides imaging of the bile ducts proximal to obstructed areas and the extraluminal abdomen as important additive information. Therefore, in routine cases, initial MRCP is a widely used screening test for PSC and currently represents the most cost-effective approach.<sup>68,69</sup> However, ERCP should remain the final arbiter if any confirmation of diagnosis is needed. In patients who are likely to benefit from a therapeutic intervention, ERCP should follow MRCP for definite treatment. Alternatively, primary ERCP in these patients with a high likelihood of intervention is still under debate. Meanwhile, liver biopsy is needed only to diagnose small-duct PSC or to exclude other diseases such as overlapping autoimmune hepatitis, which is associated with PSC in 1.4%-8% (Fig. 1).<sup>5,70-72</sup> Besides liver biopsy, transient elastography turns out to be a noninvasive technique for assessing the biliary fibrosis stage in the future.<sup>73</sup>

## CHOLANGIOCARCINOMA (CC)

The most dismal sequel of PSC is the development of CC in 8%-14% of patients.<sup>8-11</sup> A few earlier studies reported CC to be a late complication of end-stage PSC,<sup>6,74</sup> whereas more recent studies reported the development of CC after a relatively short duration of PSC and in the absence of liver cirrhosis.<sup>11,75,76</sup> Smoking, alcohol consumption, concomitant colorectal neoplasia, and a long history of IBD have been identified as risk factors for developing CC in PSC patients.<sup>75,77-79</sup> Rapid clinical deterioration with jaundice, weight loss associated with an appreciable rise in serum bilirubin, and abdominal discomfort were considered indicators for CC.<sup>7,78,80</sup> Additionally, monitoring of the tumor marker carbohydrate antigen 19-9 in serum was described to indicate CC development in PSC patients; however, given the relatively low sensitivity of this marker, its suitability for cancer screening is discussed controversially.<sup>81,82</sup>

Ultrasonography, computed tomography scanning, and MRCP have inadequate sensitivity to distinguish CC from benign stenoses in PSC.<sup>83</sup> In 2 studies from Denmark and Sweden, positron emission tomography was reported to detect also small CC with a high accuracy, but in another recent study from Belgium, these results could not be confirmed.<sup>84-86</sup> Endoscopic brush cytology with specificity in the range of 89%-100% for malignancy and a sensitivity of only 69%-75% has substantial limitations.<sup>87-89</sup> Biliary fluorescence in situ hybridization and digital image analysis are more sensitive and virtually as specific as standard cytology for the detection of bile duct malignancies and may be incorporated into cytological evaluations in the future.<sup>90-92</sup> Recently, 2 prospective studies demonstrated that transpapillary cholangioscopy and intraductal ultra-



**Figure 2. Therapeutic algorithm in patients with primary sclerosing cholangitis and cholangiocarcinoma. Resectable patients preferably undergo surgical resection as a potentially curative approach. In more advanced stages, endoscopic stenting is the first step in the management to reconstitute biliary drainage. Patients without metastases may undergo local treatment such as photodynamic therapy or radiochemotherapy. Cholangiocarcinoma is considered a contraindication for OLT in most centers but may be intended for selected patients (for example, Mayo criteria) after extensive preoperative treatment within controlled studies. Systemic chemotherapy represents the only treatment option in metastatic patients. Abbreviations: ERCP, endoscopic retrograde cholangiopancreatography; OLT, orthotopic liver transplantation; PTC, percutaneous transhepatic cholangiodrainage.**

sound significantly contribute to the discrimination of malignant bile duct stenoses from benign ones.<sup>93,94</sup>

Nevertheless, the demanding task of an early diagnosis of CC is still unsolved. Unfortunately, in the majority of PSC patients, CC is still detected at an advanced stage, and this leaves open only palliative therapy with survival rarely beyond 1 year.<sup>11</sup> Besides fluorouracil-based, platin-based, or gemcitabine-based chemotherapy with limited remission rates, these palliative approaches include biliary stenting and photodynamic therapy, which provide symptom relief and may improve survival, as recently reported for photodynamic therapy.<sup>95-97</sup> Surgical resection of CC is a therapeutic option only in limited tumor stages with reported 5-year survival rates of about 30%.<sup>98,99</sup> In PSC patients with nonmetastatic and limited CC (for example, according to the Mayo criteria), liver transplantation following radiochemotherapy is a very promising treatment option in experienced centers.<sup>100-102</sup> An algorithm of therapeutic options in PSC patients with CC is illustrated in Fig. 2.

## NATURAL HISTORY AND PROGNOSIS

PSC is a disease with a variable clinical course, but spontaneous resolution does not occur. Progressive obliteration of the biliary tree leads to biliary cirrhosis and its complications such as portal hypertension and liver failure.<sup>5,103</sup> Therefore, a wide spectrum of disease severity exists, ranging from patients who present with advanced liver disease requiring liver transplantation within a short time to those who remain asymptomatic for decades. In addition to the interindividual variability in the rate of progression, the development of CC, which may occur at any time, determines the natural course of

PSC. Median survival from time of diagnosis to death or liver transplantation is estimated to be between 9 and 18 years and increases to 26 years if only death is used as a single endpoint.<sup>5,8-10,12,26</sup> Asymptomatic patients have a significantly better prognosis than those with symptoms, but up to 17% of asymptomatic patients present with cirrhosis on liver biopsy at the time of diagnosis.<sup>12,28</sup> Even for those patients, the estimated survival rate without liver failure is 75% at 7 years versus 96% for comparable age-matched and sex-matched healthy individuals.<sup>53</sup> In 3 studies with extended follow-up, higher survival rates have also been demonstrated in patients with small-duct PSC compared to patients with classical PSC, and no development of CC was found. Some patients, however, progress to classic PSC and/or end-stage liver disease with consequent necessity of OLT.<sup>59-61</sup>

On the basis of clinical variables proven to correlate independently with prognosis, predicting survival is of great importance for defining a strategy of therapy and for timing OLT. Thus, many prognostic models and risk scores have been constructed (Table 1). Most of the models include age and serum bilirubin. Kim and co-workers<sup>104</sup> developed the revised Mayo score on the basis of the course of disease in 486 PSC patients seen at 3 referral centers.<sup>104</sup> In this score, the need for liver biopsy has been eliminated, and thus the most important drawback of previous models is avoided.

However, the mainstay of diagnosis has been cholangiography, and therefore it seems obvious to develop predictors based on cholangiographic abnormalities. A recent study from the Netherlands demonstrated that a cholangiographic classification system reflects disease stage and has the potential to serve as a predictor in determining prognosis.<sup>10</sup> In a more recent study with

TABLE 1. Variables Used in Selected Prognostic Models for Primary Sclerosing Cholangitis

	Wiesner et al. <sup>12</sup> (1989)	Farrant et al. <sup>8</sup> (1991)	Broomé et al. <sup>9</sup> (1996)	Kim et al. <sup>104</sup> (2000)	Ponsioen et al. <sup>10</sup> (2002)	Tischendorf et al. <sup>5</sup> (2007)
Age	+	+	+	+	+	+
Bilirubin	+		+	+		+
ASAT				+		
Albumin				+		+
AP		+				
Hemoglobin	+					
IBD	+					
Variceal bleeding				+		
Hepatomegaly		+				+
Splenomegaly		+				+
Histologic stage	+	+	+			
Cholangiographic stage					+	+

**Abbreviations:** AP, alkaline phosphatase; ASAT, aspartate aminotransferase; IBD, inflammatory bowel disease.

273 PSC patients, consecutively, cholangiographic changes including the distribution of PSC manifestation as well as the presence of dominant bile duct stenosis were included together with other clinical parameters in a novel prognostic model ("PSC score").<sup>5</sup> Compared with the Model for End-Stage Liver Disease score, revised Mayo score, and Child-Pugh score, the PSC score has the highest concordance index.<sup>5</sup> Nevertheless, the major limitation of all prognostic models is the inability to predict CC development.

## MEDICAL THERAPY

Because the etiology and pathogenesis of PSC are still unknown, a specific therapy is difficult. Ursodeoxycholic acid (UDCA), a hydrophilic bile acid, is conventionally recommended for patients with PSC. UDCA appears to exert a number of effects, all of which may be generally beneficial in chronic cholestasis: a choleric effect by increasing bile flow, a direct cytoprotective effect, an indirect cytoprotective effect by displacement of the more hepatotoxic endogenous hydrophobic bile acids from the bile acid pool, an immunomodulatory effect, and down-regulation of apoptosis.<sup>105,106</sup> Numerous studies have attempted to address the clinical efficacy of UDCA in PSC (Table 2). Beuers and coworkers<sup>107</sup> performed the first randomized double-blind, placebo-controlled trial of UDCA in a dose of 13-15 mg/kg/day in a small study group and documented significant biochemical and histologic improvement. In a subsequent large randomized, placebo-controlled trial from the United States, UDCA therapy with the standard dose was also associated with improvements in serum liver abnormalities but had no effect on liver histology or liver transplant-free survival.<sup>108</sup> However, biliary enrichment of UDCA increases with increasing doses and reaches a plateau at 22 to 25 mg/kg without an increase of toxic hydrophobic bile acids.<sup>109</sup> Two pilot studies with high-dose UDCA (25-30 mg/kg/day) have reported substantial improvements in biochemical,

cholangiographic, and histologic parameters.<sup>110,111</sup> In light of these encouraging results, a European multicenter, placebo-controlled study was conducted with UDCA in a dose of 17 to 23 mg/kg/day for 5 years. A trend toward increased survival was observed in the UDCA-treated group (110 patients) compared with placebo (109 patients), but despite the relatively large number of patients recruited, the study was still insufficiently powered to produce a statistically significant result.<sup>112</sup> In addition to the effects of UDCA on the biliary tract, 3 studies have investigated the role of UDCA in prevention of colonic neoplasia in PSC patients with IBD. Two of those found a significant reduction in the risk of colonic dysplasia, but the largest study addressing this issue failed to reach statistical significance.<sup>118-120</sup> Thus, the role of UDCA in preventing CC remains to be determined.

On the basis of the hypothesis that PSC may have an immunological pathogenesis, corticosteroids and other immunosuppressants were used for treatment, but they did not result in a clinical benefit.<sup>121-124</sup> The effectiveness of therapy with the combination of prednisone, azathioprine, and UDCA requires confirmation.<sup>125</sup> Pilot studies have been performed on a range of other drugs with effects on the immune system (cladribine, pentoxifylline, and etanercept) or other targets (nicotine, pirfenidone, D-penicillamine, and colchicine), but no improvement in clinical outcome has been observed (Table 2).<sup>126-131</sup> A significant improvement of liver enzymes by the administration of silymarin could be demonstrated in a recent pilot study, but this effect needs to be confirmed in a controlled trial.<sup>132</sup>

Reductions in bone density and vitamin deficiency should be monitored during treatment of PSC patients. Supplementation with calcium and fat-soluble vitamins is appropriate, particularly in patients with advanced disease.<sup>136</sup> Pruritus is frequently observed, but treatment is sometimes difficult. Medical treatment options include, among others, cholestyramine, seroto-

TABLE 2. Medical Therapies Evaluated in Patients with Primary Sclerosing Cholangitis

Medication	Year	Number		Symptoms Improved ?	Liver		Reference
		Patients	Study Type		Biochemistry Improved?	Histology Improved?	
UDCA, 10 mg/kg/day	1991	12	Open label	Yes	Yes	n.a.	113
UDCA, 13–15 mg/kg/day	1992	6	DB, PC	No	Yes	Yes	107
UDCA, 750 mg/day	1994	20	DB, PC	No	Yes	Yes	114
UDCA, 600 mg/day	1996	59	DB, PC	n.a.	No	n.a.	115
UDCA, 13–15 mg/kg/day	1997	105	DB, PC	No	Yes	No	108
UDCA, 10 mg/kg/day	1998	48	DB	No	Yes	n.a.	116
UDCA, 20–25 mg/kg/day	2001	26	DB, PC	No	Yes	Yes	110
UDCA, 25–30 mg/kg/day	2001	30	Open label	n.a.	Yes	n.a.	111
UDCA, 8–13 mg/kg/day	2002	86	DB, PC	Yes	Yes	No	117
UDCA, 17–23 mg/kg/day	2005	110	DB, PC	No	Yes	n.a.	112
Penicillamine	1988	39	DB, PC	No	No	No	130
Colchicine, corticosteroids	1991	12	Open label	n.a.	No	No	133
Methotrexate	1994	12	DB, PC	No	No	No	121
Tacrolimus	1995	10	Open label	n.a.	Yes	No	122
Colchicine	1995	44	DB, PC	No	No	No	131
Azathioprine, corticosteroids, UDCA	1999	15	Case series	n.a.	Yes	Yes	125
Nicotine	1999	8	Open label	No	No	n.a.	128
Pentoxifylline	2000	20	Open label	No	No	n.a.	127
Budenoside	2000	21	Open label	No	Yes	Yes	134
Pirfenidone	2002	24	Open label	No	No	No	129
Etanercept	2004	10	Open label	Yes	No	n.a.	126
Mycophenolate mofetil	2004	13	Randomized	No	No	No	123
Metronidazole	2004	39	DB, PC	No	Yes	Yes	135
Silymarine	2007	30	Open label	No	Yes	n.a.	132

Abbreviations: DB, double blind; n.a., not assessed; PC, placebo-controlled; UDCA, ursodeoxycholic acid.

nin, and opioid receptor antagonists as well as rifampicin.<sup>137–140</sup>

## ENDOSCOPIC TREATMENT

During the natural course of PSC, many patients experience worsening of symptoms such as pruritus, abdominal pain, fever with chills, and jaundice due to impeded biliary drainage. In a portion of these patients, cholestasis is due to dominant stenoses that develop in up to 50% of PSC patients.<sup>141,142</sup> Dominant biliary stenoses inhibit bile flow, increase biliary back pressure, and may lead to progressive deterioration of liver function. Most importantly, dominant bile duct strictures may cause bacterial cholangitis that further contributes to liver damage.<sup>143</sup> During the past decade, several studies have shown that endoscopic therapy to maintain biliary tract patency can substantially improve both liver function tests and the clinical condition in PSC patients with dominant bile duct stenoses. First attempts to treat dominant stenoses endoscopically were made by intermittent stenting.<sup>144</sup> The use of short-term stenting for dominant strictures is associated with an improvement in symptoms and liver biochemistry in a small number of patients.<sup>145,146</sup> However, a frequent problem with this procedure is early occlusion of the endoprosthesis predisposing to bacterial infection.<sup>143,147</sup> Therefore, balloon dilatation has be-

come the preferred endoscopic therapy. Actuarial survival was reported to be improved following balloon dilatation of biliary strictures among 106 patients.<sup>141</sup> The same results were obtained by 2 other retrospective analyses.<sup>148,149</sup> In most cases, however, a single dilatation is not sufficient because of restenosis, and repeated dilatations over the years are necessary until the bile duct remains open. Stenting after balloon dilatation does not result in an additional benefit.<sup>147</sup> The important role of antibiotics in all PSC patients who undergo endoscopic procedures has been demonstrated.<sup>150</sup> In all patients with dominant bile duct stenoses, extensive diagnostic efforts should be made in addition to endotherapy to exclude malignancy.<sup>93,94</sup> It is noteworthy that, despite multiple studies claiming endotherapy to be efficacious in treating the signs and symptoms of PSC, there have been no prospective, placebo-controlled trials demonstrating efficacy of this strategy.

## ORTHOTOPIC LIVER TRANSPLANTATION (OLT)

OLT is an effective therapy for PSC and the only life-saving option for end-stage disease. PSC is the fifth most common indication for OLT in the United States, and in some areas, such as the Scandinavian countries, PSC is even the leading indication for OLT.<sup>17,18</sup> Excellent long-term outcome has been reported with 5-year

patient survival rates of approximately 85%.<sup>16,151,152</sup> However, retransplantation rates are higher for patients with PSC than for patients with other diagnoses (9.6% versus 4.9%). Predictors of retransplantation are either an episode of early rejection or vascular thrombosis.<sup>152</sup>

Timing OLT in patients with PSC represents a particular problem, primarily because of the difficult prediction of the disease course as well as the increased and unpredictable risk of CC. According to recent studies, persistent elevation of serum bilirubin, cholangiographic findings, and rate of progression of the biliary changes might be the most reliable parameters for timing OLT.<sup>5,10</sup> However, the decision to list a PSC patient for OLT should be made on the basis of all clinical signs, biochemical parameters, and cholangiographic findings. According to a study from Maheshwari and co-workers,<sup>153</sup> there is no justification for performing preemptive OLT to reduce the potential risk for developing CC. Because of the high recurrence rates and a 5-year survival rate of only 5 to 35%, established CC is considered a contraindication for liver transplantation in most centers.<sup>154-156</sup> On the other hand, innovative approaches using neoadjuvant radiochemotherapy with subsequent OLT achieve good results of outcome for highly selected patients with localized CC.<sup>100-102</sup>

In the last years, increasing evidence has emerged that PSC recurs after OLT. The diagnosis of recurrent PSC is a challenge because biliary strictures in the allograft might be also caused by medications, infections, ischemia, chronic rejection, or anastomosis bile duct stricture. The recurrence rate is estimated to be between 5% and 37%, and the variation of frequency is explained by differences in the diagnostic criteria and duration of follow-up.<sup>157-159</sup> To date, patient and graft survival do not appear to be negatively affected by disease recurrence in the intermediate term of follow-up.

The course of IBD following OLT is highly variable, but increased activity is observed in about 30% of patients, with some individuals requiring proctocolectomy for symptom control.<sup>160-163</sup> Additionally, PSC patients with IBD have an increased risk for colorectal neoplasia following OLT, and cumulative incidence of colonic dysplasia of 15% at 5 years post-transplantation has been reported.<sup>164</sup> In PSC patients with ulcerative colitis, therefore, surveillance colonoscopy should be performed yearly following OLT.

## PERSPECTIVES

Placebo-controlled studies on medical therapy, mainly UDCA, that have been conducted to date are insufficiently powered to produce statistically significant results. Similarly, despite multiple studies claiming endotherapy to be efficacious in treating bile duct stenoses of PSC patients, there have been no prospective, placebo-controlled trials demonstrating the efficacy of this widely pursued strategy, and they are urgently needed for the future. As another important issue for adequate treatment of PSC patients, early detection of CC and adequate patient selection for OLT

will be challenging. Discrimination of CC from benign strictures using molecular techniques as well as standardization of eligibility criteria and extensive neoadjuvant treatment protocols before transplantation will greatly affect the prognosis of PSC patients after CC development. Finally, future insights into the etiopathogenesis of the disease may bring up new targeted therapies in the new century that may improve patient survival without transplantation.

## REFERENCES

- Hoffmann C. Verschluss der Gallenwege durch Verdickung der Wandungen. *Arch Pathol Anat Physiol Klin Med* 1867;49:206-215.
- Thorpe MEC, Scheuer PJ, Sherock S. Primary sclerosing cholangitis, the biliary tree and ulcerative colitis. *Gut* 1967;8:435-448.
- Chapman RWG, Marborgh BA, Rhodes JM, Summerfield JA, Dick, R, Scheuer PJ. Primary sclerosing cholangitis: a review of clinical features, cholangiography and hepatic histology. *Gut* 1980;21:870-877.
- LaRusso NF, Wiesner RH, Ludwig J, McCarthy RL. Primary sclerosing cholangitis. *N Engl J Med* 1984;310:899-903.
- Tischendorf JJW, Hecker H, Krüger M, Manns MP, Meier PN. Characterization, outcome, and prognosis in 273 patients with primary sclerosing cholangitis: a single center study. *Am J Gastroenterol* 2007;102:107-114.
- Wee A, Ludwig J, Coddey R, LaRusso NF, Wiesner RH. Hepatobiliary carcinoma associated with primary sclerosing cholangitis and chronic ulcerative colitis. *Hum Pathol* 1985;16:719-726.
- Rosen CB, Nagorney DM, Wiesner RH, Coffey RJ, LaRusso NF. Cholangiocarcinoma complicating primary sclerosing cholangitis. *Ann Surg* 1991;213:21-25.
- Farrant JM, Hayllar KM, Wilkinson ML, Karani J, Portmann BC, Westaby D, et al. Natural history and prognostic variables in primary sclerosing cholangitis. *Gastroenterology* 1991;100:1710-1717.
- Broomé U, Olsson R, Lödf L, Bodemar G, Hultcrantz R, Danielsson A, et al. Natural history and prognostic factor in 305 Swedish patients with primary sclerosing cholangitis. *Gut* 1996;38:610-615.
- Ponsioen CY, Vrouwenraets SME, Prawirodirdjo W, Rajaram R, Rauws EA, Mulder CJ, et al. Natural history of primary sclerosing cholangitis and prognostic value of cholangiography in a Dutch population. *Gut* 2002;51:562-566.
- Tischendorf JJW, Meier PN, Straßburg C, Klempnauer J, Hecker H, Manns MP, et al. Characterization and clinical course of hepatobiliary carcinoma in patients with primary sclerosing cholangitis. *Scand J Gastroenterol* 2006;41:1227-1234.
- Wiesner RH, Grambsch PB, Dickson ER, Ludwig J, MacCarty RL, Hunter EB, et al. Primary sclerosing cholangitis: natural history, prognostic factors and survival analysis. *Hepatology* 1989;10:430-436.
- Wilschanski M, Chait P, Wade JA, Davis L, Corey M, St Louis P, et al. Primary sclerosing cholangitis in 32 children: clinical, laboratory, and radiographic features, with survival analysis. *Hepatology* 1995;22:1415-1422.
- Gregorio GV, Portmann B, Karani J, Harrison P, Donaldson PT, Vergani D, et al. Autoimmune hepatitis/sclerosing cholangitis overlap syndrome in childhood: a 16-year prospective study. *Hepatology* 2001;33:544-553.
- Feldstein AE, Perrault J, El-Youssif M, Lindor KD, Freese DK, Angulo P. Primary sclerosing cholangitis in children:

- a long-term follow-up study. *Hepatology* 2003;38:210-217.
16. Graziadei IW, Wiesner RH, Marotta PJ, Porayko MK, Hay JE, Charlton MR, et al. Long-term results of patients undergoing liver transplantation for primary sclerosing cholangitis. *Hepatology* 1999;30:1121-1127.
  17. The Organ Procurement and Transplantation Network. Available at: <http://www.optn.org>. Accessed October 1, 2007.
  18. Nordic Liver Transplant Registry. Annual report 2006. Available at: <http://www.scandiatransplant.org>. Accessed October 1, 2007.
  19. Boberg KM, Aadland E, Jahnsen J, Raknerud N, Stiris M, Bell H. Incidence and prevalence of primary biliary cirrhosis, primary sclerosing cholangitis, and autoimmune hepatitis in a Norwegian population. *Scand J Gastroenterol* 1998;33:99-103.
  20. Bambha K, Kim WR, Talwalkar J, Torgerson H, Benson JT, Therneau TM, et al. Incidence, clinical spectrum, and outcomes of primary sclerosing cholangitis in a United States community. *Gastroenterology* 2003;125:1364-1269.
  21. Angulo P, Lindor KD. Primary sclerosing cholangitis. *Hepatology* 1999;30:325-332.
  22. Kingham JG, Kochar N, Gravenor MB. Incidence, clinical patterns, and outcomes of primary sclerosing cholangitis in South Wales, United Kingdom. *Gastroenterology* 2004;126:1929-1930.
  23. Escorsell A, Parés A, Rodés J, Solís-Herruzo JA, Miras M, de la Morena E, for the Spanish Association for the Study of the Liver. Epidemiology of primary sclerosing cholangitis in Spain. *J Hepatol* 1994;21:787-791.
  24. Ang TL, Fock KM, Ng TM, Teo EK, Chua TS, Tan JY. Clinical profile of primary sclerosing cholangitis in Singapore. *J Gastroenterol Hepatol* 2002;17:908-913.
  25. Hurlburt KJ, McMahon BJ, Deubner H, Hsu-Trawinski B, Williams JL, Kowdley KV. Prevalence of autoimmune liver disease in Alaska natives. *Am J Gastroenterol* 2002;97:2402-2407.
  26. Helzberg JH, Petersen JM, Boyer JL. Improved survival with primary sclerosing cholangitis. A review of clinicopathologic features and comparison of symptomatic and asymptomatic patients. *Gastroenterology* 1987;92:1869-1875.
  27. Schrupf E, Abdelnoor M, Fausa O, Elgjo K, Jenssen E, Kolmannskog F. Risk factors in primary sclerosing cholangitis. *J Hepatol* 1994;21:1061-1066.
  28. Okolicsanyi L, Fabris L, Viaggi S, Carulli N, Podda M, Ricci G, for the Italian PSC Study Group. Primary sclerosing cholangitis: clinical presentation, natural history and prognostic variables: an Italian multicentre study. *Eur J Gastroenterol Hepatol* 1996;8:685-691.
  29. Kochhar R, Goenka MK, Das K, Nagi B, Bhasin DK, Chawla YK, et al. Primary sclerosing cholangitis: an experience from India. *J Gastroenterol Hepatol* 1996;11:429-433.
  30. Takikawa H, Manabe T. Primary sclerosing cholangitis in Japan: analysis of 192 cases. *J Gastroenterol* 1997;32:134-137.
  31. Schrupf E, Elgjo K, Fausa O, Gjone E, Kolmannskog F, Ritland S. Sclerosing cholangitis in ulcerative colitis. *Scand J Gastroenterol* 1980;15:689-697.
  32. Olsson R, Danielsson A, Jarnerot G, Lindstrom E, Loof L, Rolny P, et al. Prevalence of primary sclerosing cholangitis in patients with ulcerative colitis. *Gastroenterology* 1991;100:1319-1323.
  33. Broome U, Glaumann H, Hellers G, Nilsson B, Sorstad J, Hultcrantz R. Liver disease in ulcerative colitis: an epidemiological and follow up study in the county of Stockholm. *Gut* 1994;35:84-89.
  34. Rasmussen HH, Fallingborg JF, Mortensen PB, Vyberg M, Tage-Jensen U, Rasmussen SN. Hepatobiliary dysfunction and primary sclerosing cholangitis in patients with Crohn's disease. *Scand J Gastroenterol* 1997;32:604-610.
  35. Bernstein CN, Wajda A, Svenson LW, MacKenzie A, Koehoorn M, Jackson M, et al. The epidemiology of inflammatory bowel disease in Canada: a population-based study. *Am J Gastroenterol* 2006;101:1559-1568.
  36. Angulo P, Peter JB, Gershwin ME, DeSotel CK, Shoenfeld Y, Ahmed AE, et al. Serum autoantibodies in patients with primary sclerosing cholangitis. *J Hepatol* 2000;32:182-187.
  37. Worthington J, Cullen S, Chapman R. Immunopathogenesis of primary sclerosing cholangitis. *Clin Rev Allergy Immunol* 2005;28:93-103.
  38. Bergquist A, Lindberg G, Saarinen S, Broome U. Increased prevalence of primary sclerosing cholangitis among first-degree relatives. *J Hepatol* 2005;42:252-256.
  39. Norris S, Kondeatis E, Collins R, Satsangi J, Clare M, Chapman R, et al. Mapping MHC-encoded susceptibility and resistance in primary sclerosing cholangitis: the role of MICA polymorphism. *Gastroenterology* 2001;120:1475-1482.
  40. Donaldson PT, Norris S. Evaluation of the role of MHC class II alleles, haplotypes and selected amino acid sequences in primary sclerosing cholangitis. *Autoimmunity* 2002;35:555-564.
  41. Mehal WZ, Lo YM, Wordsworth BP, Neuberger JM, Hubscher SC, Fleming KA, Chapman RW. HLA DR4 is a marker for rapid disease progression in primary sclerosing cholangitis. *Gastroenterology* 1994;106:160-167.
  42. Olerup O, Olsson R, Hultcrantz R, Broome U. HLA-DR and HLA-DQ are not markers for rapid disease progression in primary sclerosing cholangitis. *Gastroenterology* 1995;108:870-878.
  43. Satsangi J, Chapman RW, Haldar N, Donaldson P, Mitchell S, Simmons J, et al. A functional polymorphism of the stromelysin gene (MMP-3) influences susceptibility to primary sclerosing cholangitis. *Gastroenterology* 2001;121:124-130.
  44. Mitchell SA, Grove J, Spurkland A, Boberg KM, Fleming KA, Day CP, et al. Association of the tumour necrosis factor alpha-308 but not the interleukin 10-627 promoter polymorphism with genetic susceptibility to primary sclerosing cholangitis. *Gut* 2001;49:288-294.
  45. Sheth S, Shea JC, Bishop MD, Chopra S, Regan MM, Malmberg E, et al. Increased prevalence of CFTR mutations and variants and decreased chloride secretion in primary sclerosing cholangitis. *Hum Genet* 2003;113:286-292.
  46. Fickert P, Fuchsbichler A, Wagner M, Zollner G, Kaser A, Tilg H, et al. Regurgitation of bile acids from leaky bile ducts causes sclerosing cholangitis in Mdr2 (Abcb4) knockout mice. *Gastroenterology* 2004;127:261-274.
  47. Pauli-Magnus C, Kerb R, Fattinger K, Lang T, Anwald B, Kullak-Ublick GA, et al. BSEP and MDR3 haplotype structure in healthy Caucasians, primary biliary cirrhosis and primary sclerosing cholangitis. *Hepatology* 2004;39:779-791.
  48. Rosmorduc O, Hermelin B, Boelle PY, Poupon RE, Poupon R, Chazouilleres O. ABCB4 gene mutations and primary sclerosing cholangitis. *Gastroenterology* 2004;126:1220-1222.
  49. Strazzabosco M, Fabris L, Spirli C. Pathophysiology of cholangiopathies. *J Clin Gastroenterol* 2005;39:90-102.
  50. Spirli C, Fabris L, Duner E, Fiorotto R, Ballardini G, Roskams T, et al. Cytokine-stimulated nitric oxide production inhibits adenylyl cyclase and cAMP-dependent

- secretion in cholangiocytes. *Gastroenterology* 2003;124:737-753.
51. Duerr RH, Targan SR, Landers CJ, LaRusso NF, Lindsay KL, Wiesner RH, et al. Neutrophil cytoplasmic antibodies: a link between primary sclerosing cholangitis and ulcerative colitis. *Gastroenterology* 1991;100:1385-1391.
  52. Bansi DS, Fleming KA, Chapman RW. Importance of antineutrophil cytoplasmic antibodies in primary sclerosing cholangitis and ulcerative colitis: prevalence, titre, and IgG subclass. *Gut* 1996;38:384-389.
  53. Porayko MK, Wiesner RH, LaRusso NF, Ludwig J, MacCarty RL, Steiner BL, et al. Patients with asymptomatic primary sclerosing cholangitis frequently have progressive disease. *Gastroenterology* 1990;98:1594-1602.
  54. Bergquist A, Said K, Broome U. Changes over a 20-year period in the clinical presentation of primary sclerosing cholangitis in Sweden. *Scand J Gastroenterol* 2007;42:88-93.
  55. Hay JE, Lindor KD, Wiesner RH, Dickson ER, Krom RA, LaRusso NF. The metabolic bone disease of primary sclerosing cholangitis. *Hepatology* 1991;14:257-261.
  56. Angulo P, Therneau TM, Jorgensen A, DeSotel CK, Egan KS, Dickson ER, et al. Bone disease in patients with primary sclerosing cholangitis: prevalence, severity and prediction of progression. *J Hepatol* 1998;29:729-735.
  57. Wiesner RH, LaRusso NF. Clinicopathologic features of the syndrome of primary sclerosing cholangitis. *Gastroenterology* 1980;79:200-206.
  58. Bhathal PS, Powell LW. Primary intrahepatic obliterating cholangitis: a possible variant of "sclerosing cholangitis". *Gut* 1969;10:886-893.
  59. Angulo P, Maor-Kendler Y, Lindor KD. Small-duct primary sclerosing cholangitis: a long-term follow-up study. *Hepatology* 2002;35:1494-1500.
  60. Björnsson E, Boberg KM, Cullen S, Fleming K, Clausen OP, Fausa O, et al. Patients with small duct primary sclerosing cholangitis have a favourable long term prognosis. *Gut* 2002;51:731-735.
  61. Broomé U, Glaumann H, Lindström E, Löf L, Almer S, Prytz H, et al. Natural history and outcome in 32 Swedish patients with small duct primary sclerosing cholangitis (PSC). *J Hepatol* 2002;36:586-589.
  62. Zen Y, Harada K, Sasaki M, Sato Y, Tsuneyama K, Haratake J, et al. IgG4-related sclerosing cholangitis with and without hepatic inflammatory pseudotumor, and sclerosing pancreatitis-associated sclerosing cholangitis: do they belong to a spectrum of sclerosing pancreatitis? *Am J Surg Pathol* 2004;28:1193-1203.
  63. Toosi MN, Heathcote J. Pancreatic pseudotumor with sclerosing pancreato-cholangitis: is this a systemic disease? *Am J Gastroenterol* 2004;99:377-382.
  64. Mendes FD, Jorgensen R, Keach J, Katzmann JA, Smyrk T, Donlinger J, et al. Elevated serum IgG4 concentration in patients with primary sclerosing cholangitis. *Am J Gastroenterol* 2006;101:2070-2075.
  65. Angulo P, Pearce DH, Johnson CD, Henry JJ, LaRusso NF, Petersen BT, et al. Magnetic resonance cholangiography in patients with biliary disease: its role in primary sclerosing cholangitis. *J Hepatol* 2000;33:520-527.
  66. Berstad AE, Aabakken L, Smith HJ, Aasen S, Boberg KM, Schrupf E. Diagnostic accuracy of magnetic resonance and endoscopic retrograde cholangiography in primary sclerosing cholangitis. *Clin Gastroenterol Hepatol* 2006;4:514-520.
  67. Moff SL, Kamel IR, Eustace J, Lawler LP, Kantsevov S, Kallou AN, et al. Diagnosis of primary sclerosing cholangitis: a blinded comparative study using magnetic resonance cholangiography and endoscopic retrograde cholangiography. *Gastrointest Endosc* 2006;64:219-223.
  68. Talwalkar JA, Angulo P, Johnson CD, Petersen BT, Lindor KD. Cost-minimization analysis of MRC versus ERCP for the diagnosis of primary sclerosing cholangitis. *Hepatology* 2004;40:39-45.
  69. Meagher S, Yusoff I, Kennedy W, Martel M, Adam V, Barkun A. The roles of magnetic resonance and endoscopic retrograde cholangiopancreatography (MRCP and ERCP) in the diagnosis of patients with suspected sclerosing cholangitis: a cost-effectiveness analysis. *Endoscopy* 2007;39:222-228.
  70. Kaya M, Angulo P, Lindor KD. Overlap of autoimmune hepatitis and primary sclerosing cholangitis: an evaluation of a modified scoring system. *J Hepatol* 2000;33:537-542.
  71. van Buuren HR, van Hoogstraten HJE, Terkivatan T, Schalm SW, Vleggaar FP. High prevalence of autoimmune hepatitis among patients with primary sclerosing cholangitis. *J Hepatol* 2000;33:543-548.
  72. Burak KW, Angulo P, Lindor KD. Is there a role for liver biopsy in primary sclerosing cholangitis? *Am J Gastroenterol* 2003;98:1155-1158.
  73. Corpechot C, El Naggar A, Poujol-Robert A, Ziol M, Wendum D, Chazouillères O, et al. Assessment of biliary fibrosis by transient elastography in patients with PBC and PSC. *Hepatology* 2006;43:1118-1124.
  74. MacCarty RL, LaRusso NF, May GR, Bender CE, Wiesner RH, King JE, et al. Cholangiocarcinoma complicating primary sclerosing cholangitis: cholangiographic appearances. *Radiology* 1985;156:43-46.
  75. Leidenius M, Höckerstedt K, Broomé U, Ericzon B-G, Friman S, Olausson M, et al. Hepatobiliary carcinoma in primary sclerosing cholangitis: a case control study. *J Hepatol* 2001;34:792-798.
  76. Boberg KM, Berquist A, Mitchell S, Pares A, Rosina F, Broomé U, et al. Cholangiocarcinoma in primary sclerosing cholangitis: risk factors and clinical presentation. *Scand J Gastroenterol* 2002;10:1205-1211.
  77. Broomé U, Löfberg R, Veress B, Eriksson LS. Primary sclerosing cholangitis and ulcerative colitis: evidence for increased neoplastic potential. *Hepatology* 1995;22:1404-1408.
  78. Berquist A, Glaumann H, Persson B, Broomé U. Risk factors and clinical presentation of hepatobiliary carcinoma in patients with primary sclerosing cholangitis: a case-control study. *Hepatology* 1998;27:311-316.
  79. Chalasani N, Baluyut A, Ismail A, Zaman A, Sood G, Ghalib R, et al. Cholangiocarcinoma in patients with primary sclerosing cholangitis: a multicenter case-control study. *Hepatology* 2000;31:7-11.
  80. Miros M, Kerlin P, Walker N, Harper J, Lynch S, Strong R. Predicting cholangiocarcinoma in patients with primary sclerosing before transplantation. *Gut* 1991;33:1369-1373.
  81. Björnsson E, Kilander A, Olsson R. Ca19-9 and CEA are unreliable markers for cholangiocarcinoma in patients with primary sclerosing cholangitis. *Liver* 1999;19:510-508.
  82. Hultcrantz R, Olsson R, Danielsson A, Jarnerot G, Loof L, Ryden BO, et al. A 3-year prospective study on serum tumor markers used for detecting cholangiocarcinoma in patients with primary sclerosing cholangitis. *J Hepatol* 1999;30:669-673.
  83. Campbell WL, Ferris JV, Holbert BL, Thaete FL, Baron RL. Biliary tract carcinoma complicating primary sclerosing cholangitis: evaluation with CT, cholangiography, US, and MR imaging. *Radiology* 1998;207:41-50.
  84. Keiding S, Hansen SB, Rasmussen HH, Gee A, Kruse A, Roelsgaard K, et al. Detection of cholangiocarcinoma in primary sclerosing cholangitis by positron emission tomography. *Hepatology* 1998;28:700-706.

85. Fevery J, Buchel O, Nevens F, Verslype C, Stroobants S, Van Steenberghe W. Positron emission tomography is not a reliable method for the early diagnosis of cholangiocarcinoma in patients with primary sclerosing cholangitis. *J Hepatol* 2005;43:358-360.
86. Prytz H, Keiding S, Björnsson E, Broomé U, Almer S, Castedal M, et al. Dynamic FDG-PET is useful for detection of cholangiocarcinoma in patients with PSC listed for liver transplantation. *Hepatology* 2006;44:1572-1580.
87. Ponsioen CY, Vrouenraets SME, van Milligen de Witt AWM, Sturm P, Tascilar M, Offerhaus GJA, et al. Value of brush cytology for dominant strictures in primary sclerosing cholangitis. *Endoscopy* 1999;31:305-309.
88. Lindberg B, Arnelo U, Bergquist A, Thörne A, Hjerpe A, Granqvist S et al. Diagnosis of biliary strictures in conjunction with endoscopic retrograde cholangiopancreatography, with special reference to patients with primary sclerosing cholangitis. *Endoscopy* 2002;34:909-916.
89. Boberg KM, Jepsen P, Clausen OP, Foss A, Aabakken L, Schruppf E. Diagnostic benefit of biliary brush cytology in cholangiocarcinoma in primary sclerosing cholangitis. *J Hepatol* 2006;45:568-574.
90. Kipp BR, Stadheim LM, Halling SA, Pochron NL, Harmesen S, Nagorney DM, et al. A comparison of routine cytology and fluorescence in situ hybridization for the detection of malignant bile duct strictures. *Am J Gastroenterol* 2004;99:1675-1681.
91. Moreno Luna LE, Kipp B, Halling KC, Sebo TJ, Kremers WK, Roberts LR, et al. Advanced cytologic techniques for the detection of malignant pancreatobiliary strictures. *Gastroenterology* 2006;131:1064-1072.
92. DeHaan RD, Kipp BR, Smyrk TC, Abraham SC, Roberts LR, Halling KC. An assessment of chromosomal alterations detected by fluorescence in situ hybridization and p16 expression in sporadic and primary sclerosing cholangitis-associated cholangiocarcinomas. *Hum Pathol* 2007;38:491-499.
93. Tischendorf JJW, Krüger M, Trautwein C, Duckstein N, Schneider A, Manns MP, et al. Cholangioscopic characterization of dominant bile duct stenoses in patients with primary sclerosing cholangitis. *Endoscopy* 2006;38:665-669.
94. Tischendorf JJW, Meier PN, Schneider A, Manns MP, Krüger M. Transpapillary intraductal ultrasound in the evaluation of dominant bile duct stenoses in patients with primary sclerosing cholangitis. *Scand J Gastroenterol* 2007;42:1011-1017.
95. Khan SA, Thomas HC, Davidson BR, Taylor-Robinson SD. Cholangiocarcinoma. *Lancet* 2005;366:1303-1314.
96. Ortner ME, Caca K, Berr F, Liebetruith J, Mansmann U, Huster D et al. Successful photodynamic therapy for nonresectable cholangiocarcinoma: a randomized prospective study. *Gastroenterology* 2003;125:1355-1363.
97. Zoepf T, Jakobs R, Arnold JC, Apel D, Riemann JF. Palliation of nonresectable bile duct cancer: improved survival after photodynamic therapy. *Am J Gastroenterol* 2005;100:2426-2430.
98. DeOliveira ML, Cunningham SC, Cameron JL, Kamangar F, Winter JM, Lillemoe KD. Cholangiocarcinoma: thirty-one-year experience with 564 patients at a single institution. *Ann Surg* 2007;245:755-762.
99. Malhi H, Gores GJ. Review article: the modern diagnosis and therapy of cholangiocarcinoma. *Aliment Pharmacol Ther* 2006;23:1287-1296.
100. De Vreede I, Steers J, Burch P, Rosen C, Gunderson L, Haddock M, et al. Prolonged disease-free survival after orthotopic liver transplantation plus adjuvant chemoradiation for cholangiocarcinoma. *Liver Transpl* 2000;6:309-316.
101. Rea DJ, Heimbach JK, Rosen CB, Haddock MG, Alberts SR, Kremers WK, et al. Liver transplantation with neoadjuvant chemoradiation is more effective than resection for hilar cholangiocarcinoma. *Ann Surg* 2005;242:451-461.
102. Heimbach JK, Gores GJ, Haddock MG, Alberts SR, Pedersen R, Kremers W, et al. Predictors of disease recurrence following neoadjuvant chemoradiotherapy and liver transplantation for unresectable perihilar cholangiocarcinoma. *Transplantation* 2006;82:1703-1707.
103. Zein CO, Lindor KD, Angulo P. Prevalence and predictors of esophageal varices in patients with primary sclerosing cholangitis. *Hepatology* 2004;39:204-210.
104. Kim WR, Therneau TM, Wiesner RH, Poterucha JJ, Benson AT, Malinchoc M, et al. Revised natural history model for primary sclerosing cholangitis. *Mayo Clin Proc* 2000;75:688-694.
105. Hempling W, Dilger K, Beuers U. Systematic review: ursodeoxycholic acid—adverse effects and drug interactions. *Aliment Pharmacol Ther* 2003;18:963-972.
106. Beuers U. Drug insight: Mechanisms and sites of action of ursodeoxycholic acid in cholestasis. *Nat Clin Pract Gastroenterol Hepatol* 2006;3:318-328.
107. Beuers U, Spengler U, Kruijs W, Aydemir U, Wiebecke B, Heldwein W, et al. Ursodeoxycholic acid for treatment of primary sclerosing cholangitis: a placebo-controlled trial. *Hepatology* 1992;16:707-714.
108. Lindor KD, for the Mayo Primary Sclerosing Cholangitis-Ursodeoxycholic Acid Study Group. Ursodiol for primary sclerosing cholangitis. *N Engl J Med* 1997;336:691-695.
109. Rost D, Rudolph G, Kloeters-Plachky P, Stiehl A. Effect of high-dose ursodeoxycholic acid on its biliary enrichment in primary sclerosing cholangitis. *Hepatology* 2004;40:693-698.
110. Mitchell SA, Bansal DS, Hunt N, Von Bergmann K, Fleming KA, Chapman RW. A preliminary trial of high-dose ursodeoxycholic acid in primary sclerosing cholangitis. *Gastroenterology* 2001;121:900-907.
111. Harnois DM, Angulo P, Jorgensen RA, Larusso NF, Lindor KD. High-dose ursodeoxycholic acid as a therapy for patients with primary sclerosing cholangitis. *Am J Gastroenterol* 2001;96:1558-1562.
112. Olsson R, Boberg KM, de Muckadell OS, Lindgren S, Hultcrantz R, Folvik G, et al. High-dose ursodeoxycholic acid in primary sclerosing cholangitis: a 5-year multicenter, randomized, controlled study. *Gastroenterology* 2005;129:1464-1472.
113. O'Brien CB, Senior JR, Arora-Mirchandani R, Batta AK, Salen G. Ursodeoxycholic acid for the treatment of primary sclerosing cholangitis: a 30-month pilot study. *Hepatology* 1991;14:838-847.
114. Stiehl A, Walker S, Stiehl L, Rudolph G, Hofmann WJ, Theilmann L. Effect of ursodeoxycholic acid on liver and bile duct disease in primary sclerosing cholangitis. A 3-year pilot study with a placebo-controlled study period. *J Hepatol* 1994;20:57-64.
115. De Maria N, Colantoni A, Rosenbloom E, Van Thiel DH. Ursodeoxycholic acid does not improve the clinical course of primary sclerosing cholangitis over a 2-year period. *Hepatogastroenterology* 1996;43:1472-1479.
116. van Hoogstraten HJ, Wolfhagen FH, van de Meeberg PC, Kuiper H, Nix GA, Becx MC, et al. Ursodeoxycholic acid therapy for primary sclerosing cholangitis: results of a 2-year randomized controlled trial to evaluate single versus multiple daily doses. *J Hepatol* 1998;29:417-423.
117. Okolicsanyi L, Groppo M, Floreani A, Morselli-Labate AM, Rusticali AG, Battocchia A, et al. Treatment of primary sclerosing cholangitis with low-dose ursodeoxycholic acid: results of a retrospective Italian multicenter survey. *Dig Liver Dis* 2003;35:325-331.
118. Tung BY, Emond MJ, Haggitt RC, Bronner MP, Kimmey

- MB, Kowdley KV, et al. Ursodiol use is associated with lower prevalence of colonic neoplasia in patients with ulcerative colitis and primary sclerosing cholangitis. *Ann Intern Med* 2001;134:89-95.
119. Pardi DS, Loftus EV Jr, Kremers WK, Keach J, Lindor KD. Ursodeoxycholic acid as a chemopreventive agent in patients with ulcerative colitis and primary sclerosing cholangitis. *Gastroenterology* 2003;124:889-893.
  120. Wolf JM, Rybicki LA, Lashner BA. The impact of ursodeoxycholic acid on cancer, dysplasia and mortality in ulcerative colitis patients with primary sclerosing cholangitis. *Aliment Pharmacol Ther* 2005;22:783-788.
  121. Knox TA, Kaplan MM. A double-blind controlled trial of oral-pulse methotrexate therapy in the treatment of primary sclerosing cholangitis. *Gastroenterology* 1994;106:494-499.
  122. Van Thiel DH, Carroll P, Abu-Elmagd K, Rodriguez-Rilo H, Irish W, McMichael J, et al. Tacrolimus (FK 506), a treatment for primary sclerosing cholangitis: results of an open-label preliminary trial. *Am J Gastroenterol* 1995;90:455-459.
  123. Sterling RK, Salvatori JJ, Luketic VA, Sanyal AJ, Fulcher AS, Stravitz RT, et al. A prospective, randomized-controlled pilot study of ursodeoxycholic acid combined with mycophenolate mofetil in the treatment of primary sclerosing cholangitis. *Aliment Pharmacol Ther* 2004;20:943-949.
  124. Wagner A. Azathioprine treatment in primary sclerosing cholangitis. *Lancet* 1971;2:663-664.
  125. Schramm C, Schirmacher P, Helmreich-Becker I, Gerken G, zum Buschenfelde KH, Lohse AW. Combined therapy with azathioprine, prednisolone, and ursodiol in patients with primary sclerosing cholangitis. A case series. *Ann Intern Med* 1999;131:943-946.
  126. Epstein MP, Kaplan MM. A pilot study of etanercept in the treatment of primary sclerosing cholangitis. *Dig Dis Sci* 2004;49:1-4.
  127. Bharucha AE, Jorgensen R, Lichtman SN, LaRusso NF, Lindor KD. A pilot study of pentoxifylline for the treatment of primary sclerosing cholangitis. *Am J Gastroenterol* 2000;95:2338-2342.
  128. Angulo P, Bharucha AE, Jorgensen RA, DeSotel CK, Sandborn WJ, Larusso NF, et al. Oral nicotine in treatment of primary sclerosing cholangitis: a pilot study. *Dig Dis Sci* 1999;44:602-607.
  129. Angulo P, MacCarty RL, Sylvestre PB, Jorgensen RA, Wiesner RH, LaRusso NA, et al. Pirfenidone in the treatment of primary sclerosing cholangitis. *Dig Dis Sci* 2002;47:157-161.
  130. LaRusso NF, Wiesner RH, Ludwig J, MacCarty RL, Beaver SJ, Zinsmeister AR. Prospective trial of penicillamine in primary sclerosing cholangitis. *Gastroenterology* 1988;95:1036-1042.
  131. Olsson R, Broomé U, Danielsson A, Hägerstrand I, Järnerot G, Löf L, et al. Colchicine treatment of primary sclerosing cholangitis. *Gastroenterology* 1995;108:1199-1203.
  132. Angulo P, Jorgensen RA, Kowdley KV, Lindor KD. Silymarin in the treatment of patients with primary sclerosing cholangitis: an open-label pilot study. *Dig Dis Sci* 2007. Available at: <http://www.springer.com>. DOI: 10.1007/570620-007-0052-6.
  133. Lindor KD, Wiesner RH, Colwell LJ, Steiner B, Beaver S, LaRusso NF. The combination of prednisone and colchicine in patients with primary sclerosing cholangitis. *Am J Gastroenterol* 1991;86:57-61.
  134. Angulo P, Batts KP, Jorgensen RA, LaRusso NA, Lindor KD. Oral budesonide in the treatment of primary sclerosing cholangitis. *Am J Gastroenterol* 2000;95:2333-2337.
  135. Färkkilä M, Karvonen AL, Nurmi H, Nuutinen H, Taavitsainen M, Pikkarainen P, et al. Metronidazole and ursodeoxycholic acid for primary sclerosing cholangitis: a randomized placebo-controlled trial. *Hepatology* 2004;40:1379-1386.
  136. Lee YM, Kaplan MM, and Practice Guideline Committee of the ACG. Management of primary sclerosing cholangitis. *Am J Gastroenterol* 2002;97:528-534.
  137. Datta DV, Sherlock S. Cholestyramine for long term relief of the pruritus complicating intrahepatic cholestasis. *Gastroenterology* 1966;50:323-332.
  138. Mayo MJ, Handem I, Saldana S, Jacobs H, Getachew Y, Rush AJ. Sertraline as a first-line treatment for cholestatic pruritus. *Hepatology* 2007;45:666-674.
  139. Wolfhagen FH, Sternieri E, Hop WC, Vitale G, Bertolotti M, Van Buuren HR. Oral naltrexone treatment for cholestatic pruritus: a double-blind, placebo-controlled study. *Gastroenterology* 1997;113:1264-1249.
  140. Tandon P, Rowe BH, Vandermeer B, Bain VG. The efficacy and safety of bile acid binding agents, opioid antagonists, or rifampin in the treatment of cholestasis-associated pruritus. *Am J Gastroenterol* 2007;102:1528-1536.
  141. Stiehl A, Rudolph G, Klöters-Plachky P, Sauer P, Walker S. Development of dominant bile duct stenoses in patients with primary sclerosing cholangitis treated with ursodeoxycholic acid: outcome after endoscopic treatment. *J Hepatol* 2002;36:151-156.
  142. Björnsson E, Lindqvist-Ottosson J, Asztely M, Olsson R. Dominant strictures in patients with primary sclerosing cholangitis. *Am J Gastroenterol* 2004;99:502-508.
  143. Pohl J, Ring A, Stremmel W, Stiehl A. The role of dominant stenoses in bacterial infections of bile ducts in primary sclerosing cholangitis. *Eur J Gastroenterol Hepatol* 2006;18:69-74.
  144. Johnson GK, Geenen JE, Venu RP, Hogan WJ. Endoscopic treatment of biliary duct strictures in sclerosing cholangitis: follow-up assessment of a new therapeutic approach. *Gastrointest Endosc* 1987;33:9-12.
  145. Van Milligen de Wit AW, van Bracht J, Rauws EA, Jones EA, Tytgat GN, Huibregtse K. Endoscopic stent therapy for dominant extrahepatic bile duct strictures in primary sclerosing cholangitis. *Gastrointest Endosc* 1996;44:293-299.
  146. Ponsioen CY, Lam K, van Milligen de Wit AW, Huibregtse K, Tytgat GN. Four years experience with short term stenting in primary sclerosing cholangitis. *Am J Gastroenterol* 1999;94:2403-2407.
  147. Kaya M, Petersen BT, Angulo P, Baron TH, Andrews JC, Gostout CJ, et al. Balloon dilation compared to stenting of dominant strictures in primary sclerosing cholangitis. *Am J Gastroenterol* 2001;96:1059-1066.
  148. Baluyut AR, Sherman S, Lehman GA, Hoen H, Chalasani N. Impact of endoscopic therapy on the survival of patients with primary sclerosing cholangitis. *Gastrointest Endosc* 2001;53:308-312.
  149. Vuddagiri SK, France R, Kozarek. Endoscopic therapy in primary sclerosing cholangitis (PSC): does the complication risk outweigh therapeutic benefit? *Gastrointest Endosc* 2004;59:AB193.
  150. Olsson R, Björnsson E, Bäckman L, Friman S, Höckerstedt K, Kaijser B, et al. Bile duct bacterial isolates in primary sclerosing cholangitis: a study of explanted livers. *J Hepatol* 1998;28:426-432.
  151. Solano E, Khakhar A, Bloch M, Quan D, McAlister V, Ghent C, et al. Liver transplantation for primary sclerosing cholangitis. *Transplant Proc* 2003;35:2431-2434.
  152. Brandsaeter B, Friman S, Broomé U, Isoniemi H, Olausson M, Bäckman L, et al. Outcome following liver transplantation for primary sclerosing cholangitis in the Nor-

- dic countries. *Scand J Gastroenterol* 2003;38:1176-1183.
153. Maheshwari A, Yoo HY, Thuluvath PJ. Long-term outcome of liver transplantation in patients with PSC: a comparative analysis with PBC. *Am J Gastroenterol* 2004;99:538-542.
154. Abu-Elmagd KM, Selby R, Iwatsuki S, Fung J, Tzakis A, Todo S, et al. Cholangiocarcinoma and sclerosing cholangitis: clinical characteristics and effect on survival after liver transplantation. *Transplant Proc* 1993;25:1124-1125.
155. Nashan B, Schlitt HJ, Tusch G, Oldhafer KJ, Ringe B, Wagner S, et al. Biliary malignancies in primary sclerosing cholangitis: timing for liver transplantation. *Hepatology* 1996;23:1105-1111.
156. Brandsaeter B, Isoniemi H, Broomé U, Olausson M, Bäckman L, Hansen B, et al. Liver transplantation for primary sclerosing cholangitis; predictors and consequences of hepatobiliary malignancy. *J Hepatol* 2004;40:815-822.
157. Graziadei IW, Wiesner RH, Batts KP, Marotta PJ, LaRusso NF, Porayko MK, et al. Recurrence of primary sclerosing cholangitis following liver transplantation. *Hepatology* 1999;29:1050-1056.
158. Vera A, Moledina S, Gunson B, Hubscher S, Mirza D, Olliff S, et al. Risk factors for recurrence of primary sclerosing cholangitis of liver allograft. *Lancet* 2002;360:1943-1944.
159. Khettry U, Keaveny A, Goldar-Najafi A, Lewis WD, Pomfret EA, Pomposelli JJ, et al. Liver transplantation for primary sclerosing cholangitis: a long-term clinicopathologic study. *Hum Pathol* 2003;34:1127-1136.
160. Shaked A, Colonna JO, Goldstein L, Busuttill RW. The interrelation between sclerosing cholangitis and ulcerative colitis in patients undergoing liver transplantation. *Ann Surg* 1992;215:598-605.
161. Miki C, Harrison JD, Gunson BK, Buckels JA, McMaster P, Mayer AD. Inflammatory bowel disease in primary sclerosing cholangitis: an analysis of patients undergoing liver transplantation. *Br J Surg* 1995;82:1114-1117.
162. Papatheodoridis GV, Hamilton M, Mistry PK, Davidson B, Rolles K, Burroughs AK. Ulcerative colitis has an aggressive course after orthotopic liver transplantation for primary sclerosing cholangitis. *Gut* 1998;43:639-644.
163. MacLean AR, Lilly L, Cohen Z, O'Connor B, McLeod RS. Outcome of patients undergoing liver transplantation for primary sclerosing cholangitis. *Dis Colon Rectum* 2003;46:1124-1128.
164. Loftus EV, Aguilar HI, Sandborn WJ, Tremaine WJ, Krom RA, Zinsmeister AR, et al. Risk of colorectal neoplasia in patients with primary sclerosing cholangitis and ulcerative colitis following orthotopic liver transplantation. *Hepatology* 1998;27:685-690.